

# Transdermal Sustained-Delivery Oxygen Improves Epithelial Healing in a Rabbit Ear Wound Model

Hakim K. Said, MD; John Hijawi, MD; Nakshatra Roy, PhD; Jon Mogford, PhD; Thomas Mustoe, MD

**Hypothesis:** Transdermal sustained-delivery oxygen therapy improves wound healing.

**Design:** Experimental study using a well-established rabbit ear model for acute wound healing.

**Setting:** Wound-healing research laboratory in a university center.

**Methods:** Four full-thickness 7-mm punch wounds were created on each ear of young, female New Zealand white rabbits. Treated ears received transdermal sustained delivery of oxygen via silicone tubing tunneled subcutaneously to a pocket under a semioclusive dressing. Oxygen production (100% oxygen at 3 mL/h continuously) relied on a small, self-contained device

connected to the silicone tubing and secured to the rabbit's back for the duration of the experiment using a body harness. Ears were harvested at each of 2 time points: day 5 and day 8.

**Results:** Histologic analysis of the wounds showed significantly greater healing at both day 5 and day 8 in response to oxygen therapy. Most significantly, epithelial wound coverage was almost doubled in treated ear wounds when compared with controls.

**Conclusion:** Our results suggest that epithelial wound healing is improved by transdermal sustained-delivery treatment with 100% oxygen.

*Arch Surg.* 2005;140:998-1004

THE IMPORTANCE OF AN adequate oxygen supply for successful wound healing has long been recognized, and in recent years, the cellular role of oxygen as a signaling molecule has also been well demonstrated. Responding to low oxygen levels, the hypoxia inducible factor signaling pathway has been identified as a potential therapeutic target.<sup>1</sup> Beyond oxygen's nutrient properties, changes in intracellular oxygen levels regulate signal transduction pathways responsible for mediating various important growth factors and multiple enzymes involved in glycolysis.<sup>2-5</sup> Moreover, its role as the essential substrate for generation of oxygen free radicals confers benefits in local resistance to infection.<sup>6,7</sup>

Oxygen as a therapeutic agent has a long history in wound healing, with a wide gamut of interventions all aimed at augmenting oxygen delivery to impaired wound-healing sites. Although arterial reconstruction is a time-proven intervention for arterial insufficiency, hyperbaric oxygen, the other principal form of increased oxygen delivery to local tissues in wound healing, has been more controver-

sial. Hyperbaric oxygen has been used extensively for more than 50 years in the treatment of ischemic wounds, largely on an empirical basis, and with a paucity of controlled clinical trials.<sup>8-12</sup> Nevertheless, in some studies, hyperbaric oxygen has shown some clear-cut benefits for wound healing,<sup>13-15</sup> and it has been accepted as an efficacious therapy for diabetic ulcers in the setting of ischemia.<sup>16-18</sup> With the recognition of oxygen as a signaling molecule, and experimental observations that intermittent hyperbaric oxygen can induce growth factors and their receptors<sup>19</sup> and enhance growth-factor activities,<sup>20</sup> there has been an increased understanding of the mechanism of action of hyperbaric oxygen therapy.<sup>21</sup>

Intermittent hyperbaric oxygen therapy involves placing a patient into a chamber with oxygen pressures of 2 atm or greater, raising the oxygen level within ischemic wounds to 300 mm Hg for a period of 1 to 2 hours, from a resting level of less than 10 mm Hg.<sup>22</sup> This therapy has the self-evident limitation of accessibility to the chamber, as well as posing issues of expense and safety. An alternative clinical strategy that has been used anecdotally involves regional oxygen therapy (either hy-

**Author Affiliations:** Wound Healing Research Lab, Division of Plastic Surgery, Feinberg School of Medicine, Northwestern University, Chicago, Ill.

perbaric or at normal pressure) by placing an extremity in a portable rigid or inflatable unit for several hours.<sup>23-25</sup> This rationale is much different from that of hyperbaric oxygen in that the oxygen is delivered locally, and its therapeutic effect is limited by diffusion across the skin surface. Few clinical studies testing this approach have been performed,<sup>26</sup> and no controlled animal models have demonstrated the efficacy of this mode of treatment.

In this study, we use a self-contained miniature device that produces continuous oxygen delivery to the local wound environment by an electrochemical reaction. It allows sustained transdermal delivery over 24 hours daily to the local wound environment. The central hypothesis of this study was to address an unanswered question: would local oxygen delivery be efficacious in an established and carefully controlled wound-healing model?<sup>27,28</sup> Second, would a miniature device delivering oxygen to the local wound environment that would allow sustained 24-hour delivery of oxygen have an amplified effect over current regional devices, which are large and nonportable and cannot be feasibly be used longer than a few hours daily?

## METHODS

### MODELS

The ischemic ear wound model was used as described previously by Ahn and Mustoe.<sup>28</sup> The technique was modified to permit transdermal sustained oxygen delivery to 1 of the 2 ischemic ears. We followed the Northwestern University (Chicago, Ill) guidelines for care and use of laboratory animals throughout this study.


Young (3- to 6-month-old), female New Zealand white rabbits were anesthetized with intramuscular xylazine and ketamine (xylazine, 16mg/kg; ketamine, 80 mg/kg) according to the university's standard protocol. Depilation and topical antibacterial preparation (povidone iodine scrub) of the pertinent surgical site were performed. Under microscopic magnification, both ears were rendered ischemic by dividing the small rostral artery and the large central artery. Care was taken to preserve all associated veins and the tiny caudal artery, which serves as the sole blood supply to the healing ear (**Figure 1**). Four full-thickness 7-mm punch wounds were then created on each ear.

### OXYGEN THERAPY

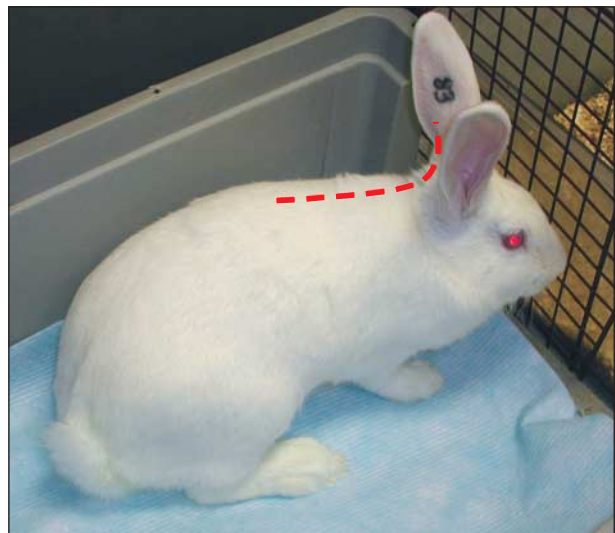
Treated ears received transdermal sustained delivery of oxygen via silicone tubing tunneled subcutaneously to a pocket under a semiocclusive dressing (**Figure 2**). Oxygen production relied on a small device (EPIFLO SD; Ogenix Corp, Cleveland, Ohio), manufacturer rated to produce 100% O<sub>2</sub> at 3 mL/h continuously based on a battery-driven electrochemical reaction. One self-contained unit (5 × 3.6 × 1.3 cm; 57 g) was connected to the silicone tubing and secured in a body harness to each rabbit for the duration of the experiment (**Figure 3**). Care was taken daily to ensure the proper seal was maintained over the wounds.

### HISTOLOGIC ANALYSIS

At either of 2 time points (day 5 or 8), the animals were anesthetized again and killed using an intracardiac injection of phe-



**Figure 1.** Ischemic rabbit ear model, perfused by tiny caudal artery after division of rostral and central arteries.



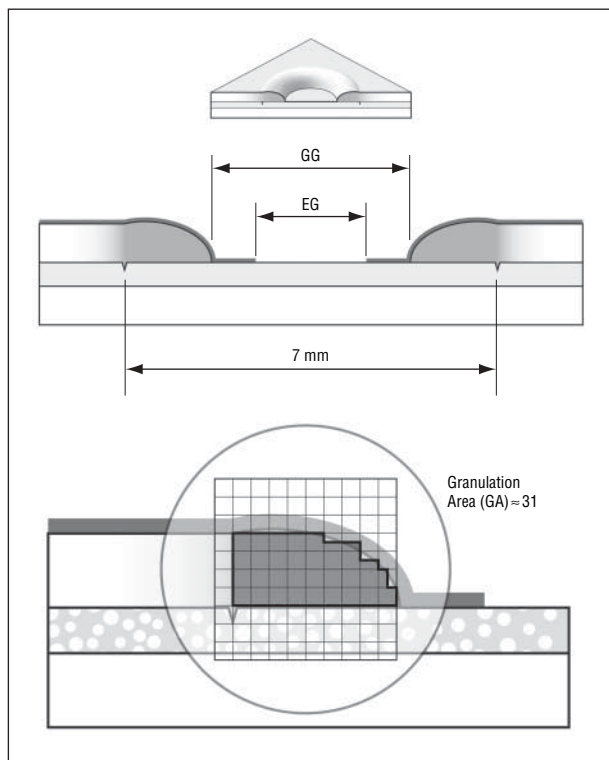
**Figure 2.** Oxygen delivery through silicone tubing tunneled subcutaneously from parascapular entry site to semiocclusive dressing over ear wounds.

nobarbital according to the university's standard protocol. Wounds were harvested and bisected; we preserved half in formalin for histologic processing and the remainder at -80° for RNA extraction.

Tissue was then processed for histologic analysis, sectioned, and stained by a dedicated histopathologist. Histologic analysis assessed 18 measurements, used in conjunction to determine cardinal wound-healing parameters in a process that has been described previously (**Figure 4** and **Figure 5**).<sup>29</sup> Blinded to treatment modality, research fellows quantitated the



**Figure 3.** Oxygen generation device (Ogenix Corp, Cleveland, Ohio) secured in body-mounted harness.



**Figure 4.** Standard histologic measurements, including granulation gap (GG), epithelial gap (EG), and reticule graded granulation area measurement.

epithelial gap, epithelial height, granulation distance, granulation height, granulation area, and peak-to-peak distance for each sagittal wound section.

An additional 14 slides underwent histologic staining using an Alcian blue protocol (pH 2.5) to quantitate provisional matrix formation (proteoglycan) after wounding, composed mostly of disaccharide-repeat glycosaminoglycan covalently linked to a protein core. Sirius red was used in a parallel staining protocol to quantitate collagen deposition. Semiquantitative grading was performed in blinded fashion, using a scoring scale for increased staining to track increased synthesis and deposition of glycosaminoglycan and collagen within the wound bed (**Figure 6**).

## REAL-TIME POLYMERASE CHAIN REACTION

The preserved tissue samples were also subjected to RNA extraction (Qiagen, Valencia, Calif). Tissue analysis was performed using quantitative polymerase chain reaction (PCR) processed on an ABI PRISM 7000 Sequence Detection System real-time PCR machine (Applied Biosystems, Foster City, Calif). Primers and probes were designed for rabbit  $\alpha$ -2 type 1 collagen 9 to assess collagen induction.

Primers and probes were designed for c-Fos, a subunit of the activator protein-1 (AP-1) transcription factor promoter, as an assay for generalized cellular keratinocyte activity.

All samples were run in triplicate and expression was measured relative to quantitated constitutive 18S ribosomal RNA activity for each sample (also run in triplicate). Delta delta cycle threshold ( $\Delta\Delta C_t$ ) values were used to determine relative expression between treatment and control groups.

## STATISTICS

Statistical analysis of histologic data was performed using analysis-of-variance multivariate analysis software to determine significance of findings in the 4 treatment groups (day 5 and day 8, control and treatment). Groups were analyzed using the Tukey honestly significant difference test to generate studentized range statistics. *P* values below .05 were considered significant. Significance of Alcian blue histologic staining and quantitative PCR results were determined using a *t* test for a probability of  $P < .05$ .

## RESULTS

### WOUND HEALING

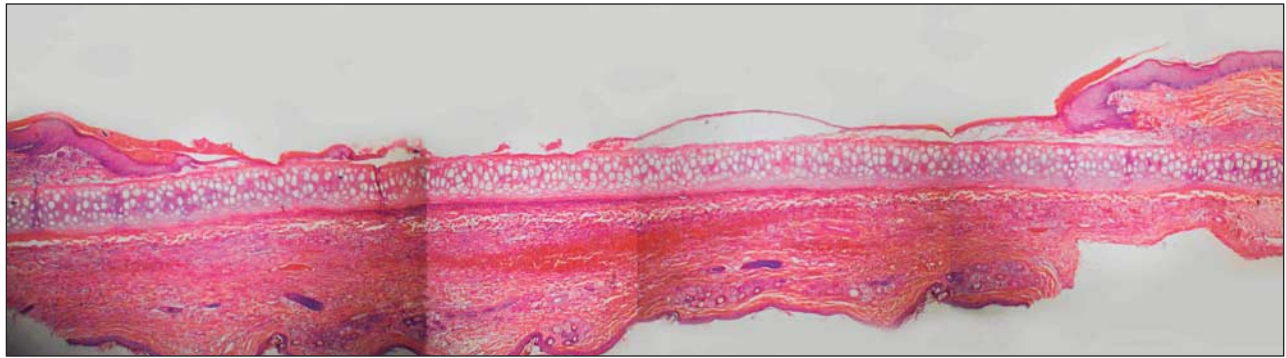
Rabbits were treated with transdermal sustained delivery of oxygen to 1 ear with the opposite ear serving as the control (**Figure 2**). Quantitative histologic analysis (**Figure 4** and **Figure 5**) of the 7-mm circular open wounds revealed an increase in epithelial wound coverage of 156% at day 8 (**Figure 7**) and 91% at day 5 (**Figure 8**). Overall mean granulation tissue volume showed a trend toward an increase but did not reach significance (**Figure 9**).

### MATRIX COMPOSITION

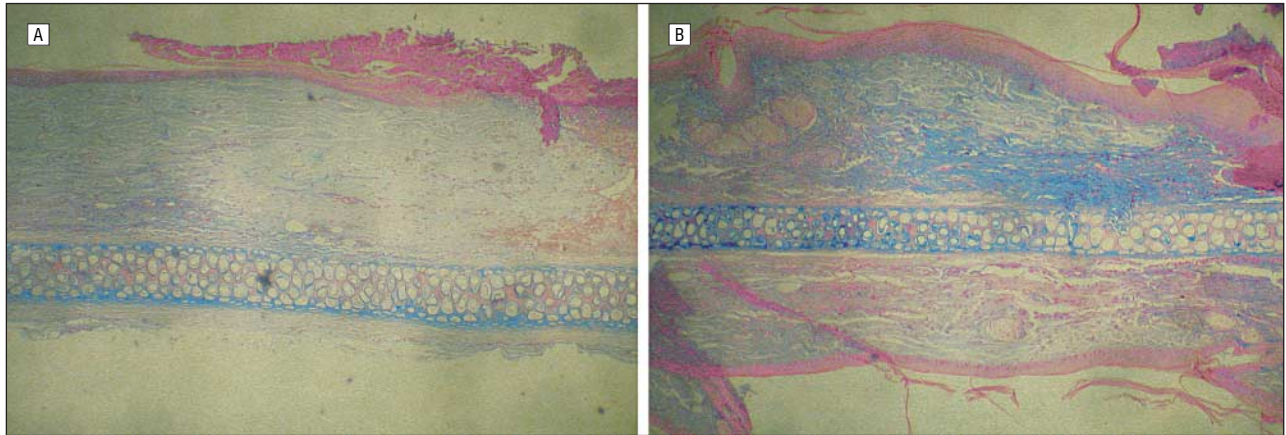
Prior reports have shown increased glycosaminoglycan production in response to oxygen-enriched environments *in vitro*.<sup>29</sup> In the current study, an analysis of the matrix composition in the granulation tissue was carried out by differential staining with Alcian blue for glycosaminoglycan content and Sirius red for collagen content. Semiquantitative analysis by a grading scale (discussed in the "Methods" section) showed increased deposition of glycosaminoglycan (**Figure 10**). Analysis of collagen content showed no differences (data not shown).

### FIBROBLAST AND KERATINOCYTE ACTIVATION

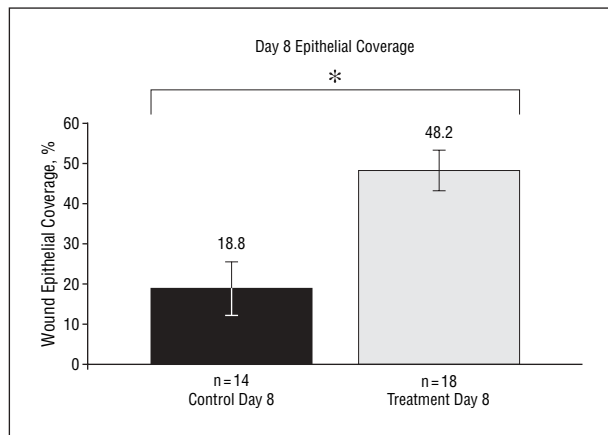
Collagen induction was also assessed by real-time PCR analysis for type 1 collagen, further confirming the histologic analysis that there were no significant differ-



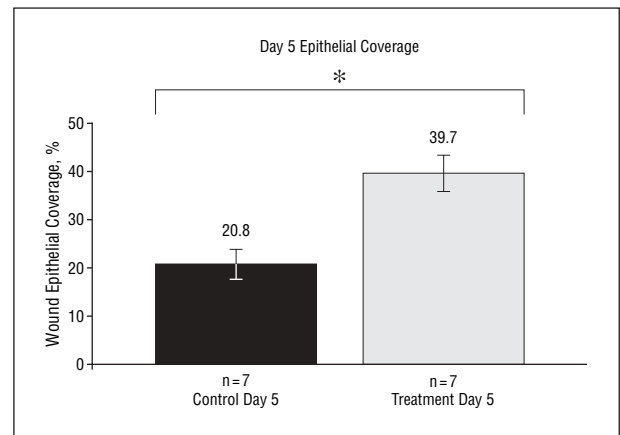
**Figure 5.** Composite image of multiple adjacent histologic fields of view.



**Figure 6.** Grading of histologic slides. A, Grade 1 Alcian blue staining, which selectively stands for glycosaminoglycans. B, Grade 4 Alcian blue staining.



**Figure 7.** Histologic analysis at day 8 shows 156% greater epithelial coverage in oxygen treatment vs control groups. Asterisk indicates  $P=.01$ .



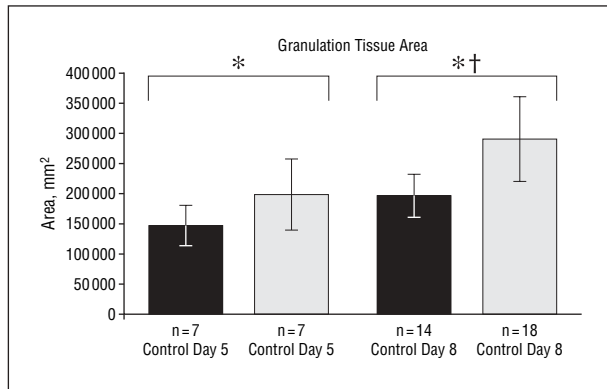
**Figure 8.** Histologic analysis at day 5 shows 91% greater epithelial coverage in oxygen treatment vs control groups. Asterisk indicates  $P=.02$ .

ences between treatment and control groups (**Figure 11**). Previous reports have used AP-1, a nuclear binding protein and signal transduction pathway molecule common to many pathways, including keratinocyte up-regulation, as an indicator of keratinocyte transcriptional activation.<sup>30</sup> Induction of AP-1 was examined in this study to further document the keratinocyte activity consistent with the histologic findings of increased epithelial coverage and epithelial proliferation. Real-time PCR analysis for changes in AP-1 showed notable differences between the oxygen and control groups (**Figure 12**), which

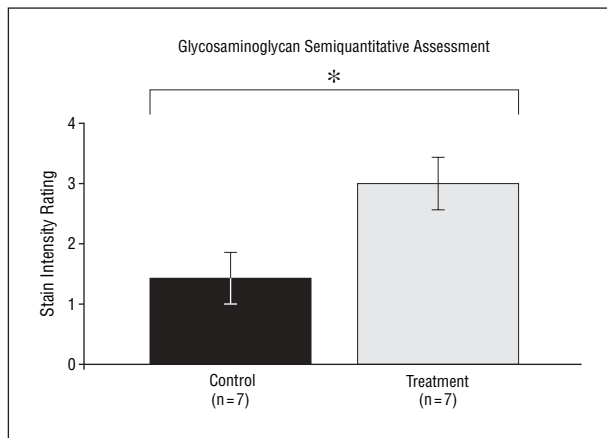
were consistent with the histologic observations and approached statistical significance ( $P=.07$ ).

#### COMMENT

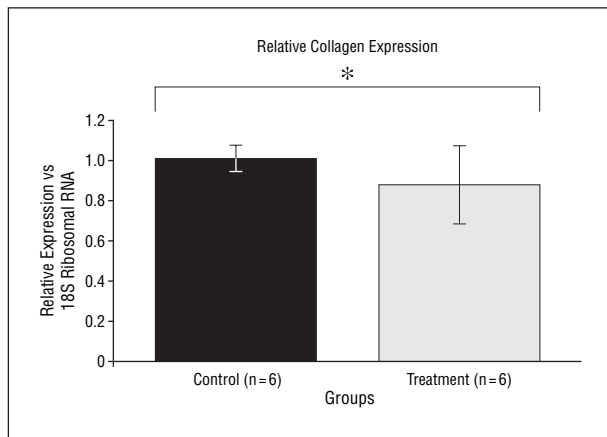
That oxygen is important to wound healing has been firmly established, from clinical successes with arterial reconstruction of ischemic extremities to quantitative comparisons of tissue oxygen tensions in healing and non-healing wounds.<sup>31,32</sup> However, there is a lack of knowledge as to the method of delivery, duration, and amount



**Figure 9.** Histologic analysis of granulation tissue area in oxygen treatment and control groups. Asterisk indicates  $P=.23$ ; dagger,  $P=.12$ .

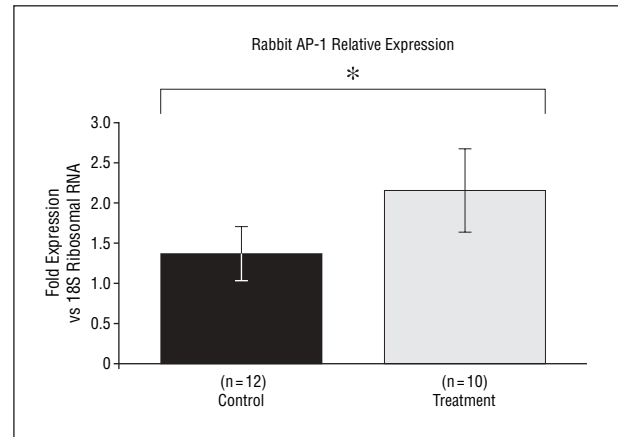


**Figure 10.** Semiquantitative analysis of Alcian blue staining for glycosaminoglycan in oxygen treatment vs control groups. Asterisk indicates  $P=.03$ .



**Figure 11.** Real-time polymerase chain reaction analysis of collagen expression relative to constitutive 18S ribosomal RNA in oxygen treatment and control groups. Asterisk indicates  $P=.54$ .

of oxygen necessary for significant wound-healing benefits. The largest body of evidence has accumulated for systemic hyperbaric oxygen delivered at 2 to 3 atm for 1 to 2 hours per 24-hour period over 1 to 4 weeks,<sup>20</sup> but there is no consensus on optimal treatment regimens and these regimens are largely empirical. The paucity of randomized prospective clinical trials meeting the highest



**Figure 12.** Real-time polymerase chain reaction analysis of activator protein-1 (AP-1) expression relative to constitutive 18S ribosomal RNA in oxygen treatment and control groups. Asterisk indicates  $P=.11$ .

standards for evidence-based medicine has meant that hyperbaric oxygen therapy has failed to earn consensus recommendation as an effective therapeutic modality, although it is gaining increased acceptance for diabetic wounds.<sup>17,18,33-35</sup> Regional oxygen therapy directed at a limb at hyperbaric or normobaric levels for varying periods of time is being marketed on the basis of anecdotal studies alone.<sup>2</sup>

Despite this, isolated studies under controlled circumstances have documented clear improvements in wound healing in response to oxygen therapy in different forms. Carefully controlled animal studies from multiple centers show significant effects of systemic hyperbaric therapy on cutaneous healing in small animal models.<sup>13,14</sup>

Studies further examining the depth of penetration of ambient hyperoxia have shown limited penetration into tissues (<1 mm), casting doubt on the possibility of effects at deeper levels.<sup>36</sup>

Target tissue selection may prove pivotal in such cases; systemic hyperbaric therapy for deep tissue problems such as mandibular osteoradionecrosis rely on oxygen enrichment of blood flow perfusion, while in superficial ulcers, increasing the depth of penetration of transdermal delivery, particularly when continuous, is more likely to be therapeutic. Given the absence of knowledge of critical levels of tissue oxygen to be therapeutic, transdermal delivery of oxygen to shallow ulcers has a potential rationale. The limitations on tissue diffusion are consistent with the findings in this study of a greater measurable effect on the superficial epithelial layer than the underlying granulation tissue. Whether the effects on granulation tissue would reach a larger magnitude in larger wounds treated for longer periods of time remains to be seen and warrants further study.

The product specifications of the oxygen generator (EPIFLO SD) rate production of oxygen at 3 mL hourly to 3 logarithms of purity (99.9%) in the model used. Bench testing by the device manufacturer has confirmed local partial pressures of between 350 and 400 mm Hg under a semioclusive membrane similar to that used in this study (manufacturer specifications). Of note, although treatment conditions were normobaric

by design, partial oxygen tension in the exposed tissues approached similar levels to tension measured in hyperbaric oxygen therapy, delivered systemically by means of blood flow.<sup>22</sup>

It is significant to note that although the effects on the epithelial component of wound healing were striking on day 8, the impact on day 5 healing was already demonstrable. Previous experimental studies on wound healing<sup>27,37,38</sup> have demonstrated a so-called "lag phase," which has been characterized as a 72-hour period of cellular activation with little activity. This suggests that transdermal sustained-delivery oxygen has a rapid onset of activity, but it is unclear whether the lag phase is accelerated or whether the augmentation in epithelial healing is accelerated enough to demonstrate the nearly 2-fold greater coverage within 48 hours after the normal lag phase.

Of relevance and potential significance in this study is the continuous nature of the therapy. Hyperbaric oxygen treatments are intermittent, and other regional oxygen-delivery systems relying on the transdermal route have also been intermittent.<sup>23-25</sup> Despite its limited penetration, the continuous delivery may offset the greater impact on deeper tissues by systemic hyperbaric oxygen delivery. Within the time frame of this study (1 week), improvement in deeper wound-healing substrates was not significant, although the magnitude of the effect was suggestive and limited by the numbers in this study. Induction of collagen synthesis was not seen.

A report has described AP-1 in assessing epithelial healing of corneal wounds as a generalized marker for keratinocyte activation.<sup>30</sup> Activation of AP-1 showed a borderline increase in our treatment group ( $P = .07$ ), consistent with the augmented epithelial healing seen in this study.

As a potential alternative to systemic hyperbaric therapy, transdermal oxygen delivery represents an easily applied and inexpensive option that can be incorporated into a wound dressing. The issues of accessibility, availability, and expense have been impediments to the more widespread use of hyperbaric oxygen treatments. To our knowledge, this study represents the first experimental or clinical study demonstrating a beneficial impact on wound healing for transdermal delivery of oxygen in a well-established animal model. A compact transdermal delivery system also opens the possibility for synergism between oxygen therapy and growth-factor therapy, which experimentally has shown promise and rationale.<sup>4,5,20</sup>

## CONCLUSIONS

Transdermal sustained-delivery oxygen significantly improves the epithelial component of ischemic wound healing in our model. We found no increased induction of collagen synthesis. The data in this study suggest it may also improve other components of ischemic healing, including granulation tissue formation, provisional matrix deposition, and cellular metabolism.

Based on these results, we report that transdermal sustained-delivery oxygen is a viable, inexpensive alter-

native to systemic hyperbaric therapy, conferring clear and significant benefits in ischemic epithelial wound healing.

Oxygen treatment in the form of hyperbaric oxygen has gained increasing acceptance for chronic wounds with an ischemic component, particularly diabetic ulcers. There has been an increasing scientific rationale for the therapeutic benefits of oxygen in conditions of hypoxic tissues. The use of topical oxygen therapy in the form of a lightweight and portable bandage has widespread potential clinical applications. Based on animal studies, use in combination with growth factors or other therapeutic agents may synergistically increase its clinical efficacy.<sup>20</sup> Further studies are warranted, especially in conjunction with therapies that augment healing by other mechanisms.

**Accepted for Publication:** December 15, 2004.

**Correspondence:** Thomas A. Mustoe, MD, Division of Plastic and Reconstructive Surgery, Northwestern University Feinberg School of Medicine, 675 North St Clair, Suite 19-250, Chicago, IL 60611 (tmustoe@nmh.org).

**Funding/Support:** The costs of the animal models were defrayed in part by a grant from Ogenix Corp, Cleveland, Ohio.

**Acknowledgment:** We thank Mel Burk of Ogenix Corp, Cleveland, Ohio, whose patience and cooperation were invaluable, as well as Srinivasin Sarangapani of ICET Labs, Norwood, Mass, who was instrumental in making certain the oxygen production devices were troublefree. We also recognize Mark Sisco, MD, for his help in preparing the final figures.

## REFERENCES

1. Marx J. How cells endure low oxygen. *Science*. 2004;303:1454-1456.
2. Davidson JD, Mustoe TA. Oxygen in wound healing: more than a nutrient. *Wound Repair Regen*. 2001;9:175-177.
3. Gordillo GM, Sen CK. Revisiting the essential role of oxygen in wound healing. *Am J Surg*. 2003;186:259-263.
4. Sen CK, Khanna S, Babior BM, Hunt TK, Ellison EC, Roy S. Oxidant-induced vascular endothelial growth factor expression in human keratinocytes and cutaneous wound healing. *J Biol Chem*. 2002;277:33284-33290.
5. Cho M, Hunt TK, Hussain MZ. Hydrogen peroxide stimulates macrophage vascular endothelial growth factor release. *Am J Physiol Heart Circ Physiol*. 2001;280:H2357-H2363.
6. Knighton DR, Halliday B, Hunt TK. Oxygen as an antibiotic: a comparison of the effects of inspired oxygen concentration and antibiotic administration on in vivo bacterial clearance. *Arch Surg*. 1986;121:191-195.
7. Knighton DR, Halliday B, Hunt TK. Oxygen as an antibiotic: the effect of inspired oxygen on infection. *Arch Surg*. 1984;119:199-204.
8. Fischer BH. Topical hyperbaric oxygen treatment of pressure sores and skin ulcers. *Lancet*. 1969;2:405-409.
9. Rosenthal AM, Schurman A. Hyperbaric treatment of pressure sores. *Arch Phys Med Rehabil*. 1971;52:413-423.
10. Stalker CG, McEwan AJ, Ledingham IM. The effect of increased oxygen in acute limb ischaemia. *Br J Surg*. 1973;60:144-148.
11. Upson AV. Topical hyperbaric oxygenation in the treatment of recalcitrant open wounds: a clinical report. *Phys Ther*. 1986;66:1408-1412.
12. Kaufman T, Alexander JW, MacMillan BG. Topical oxygen and burn wound healing: a review. *Burns Incl Therm Inj*. 1983;9:169-173.
13. Bonomo SR, Davidson JD, Tyrone JW, Lin X, Mustoe TA. Enhancement of wound healing by hyperbaric oxygen and transforming growth factor beta3 in a new chronic wound model in aged rabbits. *Arch Surg*. 2000;135:1148-1153.
14. Uhl E, Sirsjo A, Haapaniemi T, Nilsson G, Nylander G. Hyperbaric oxygen improves wound healing in normal and ischemic skin tissue. *Plast Reconstr Surg*. 1994;93:835-841.

15. Zamboni WA, Browder LK, Martinez J. Hyperbaric oxygen and wound healing. *Clin Plast Surg.* 2003;30:67-75.
16. Hammarlund C, Sundberg T. Hyperbaric oxygen reduced size of chronic leg ulcers: a randomized double-blind study. *Plast Reconstr Surg.* 1994;93:829-834.
17. Bello YM, Phillips TJ. Recent advances in wound healing. *JAMA.* 2000;283:716-718.
18. Bozzuto TM, Fife CE. Adjunctive therapies for wound healing. *JAMA.* 2000;284:40.
19. Davidson JD, Bonomo SR, Yu Y, Xia Y, Lin X, Mustoe TA. Hyperbaric oxygen as a signal transducer: upregulation of platelet derived growth factor-beta receptor in the presence of HBO and PDGF. *Undersea Hyperb Med.* 1998;25:211-216.
20. Zhao LL, Davidson JD, Wee SC, Roth SI, Mustoe TA. Effect of hyperbaric oxygen and growth factors on rabbit ear ischemic ulcers. *Arch Surg.* 1994;129:1043-1049.
21. Sen CK, Khanna S, Gordillo G, Bagchi D, Bagchi M, Roy S. Oxygen, oxidants and antioxidants in wound healing: an emerging paradigm. *Ann N Y Acad Sci.* 2002;957:239-249.
22. Siddiqui A, Davidson JD, Mustoe TA. Ischemic tissue oxygen capacitance after hyperbaric oxygen therapy: a new physiologic concept. *Plast Reconstr Surg.* 1997;99:148-155.
23. Gorman DF, Harding PE, Roberts AP, Gilligan JE, Capps RA, Parsons DW. Topical hyperbaric oxygen for treatment of diabetic foot ulcers. *Diabetes Care.* 1988;11:819.
24. Ignacio DR, Pavot AP, Azer RN, Wisotsky L. Topical oxygen therapy treatment of extensive leg and foot ulcers. *J Am Podiatr Med Assoc.* 1985;75:196-199.
25. Leslie CA, Sapico FL, Ginunas VJ, Adkins RH. Randomized controlled trial of topical hyperbaric oxygen for treatment of diabetic foot ulcers. *Diabetes Care.* 1988;11:111-115.
26. Kalliainen LK, Gordillo GM, Schlanger R, Sen CK. Topical oxygen as an adjunct to wound healing: a clinical case series. *Pathophysiology.* 2003;9:81-87.
27. Mustoe TA, Pierce GF, Morishima C, Deuel TF. Growth factor induced acceleration of tissue repair through direct and inductive activities in a rabbit dermal ulcer model. *J Clin Invest.* 1991;87:694-703.
28. Ahn ST, Mustoe TA. Effects of ischemia on ulcer wound healing: a new model in the rabbit ear. *Ann Plast Surg.* 1990;24:17-23.
29. Roberts GP, Harding KG. Stimulation of glycosaminoglycan synthesis in cultured fibroblasts by hyperbaric oxygen. *Br J Dermatol.* 1994;131:630-633.
30. Rayner TE, Yates S. Transcription factor activation in response to cutaneous injury: role of AP-1 in reepithelialization. *Wound Repair Regen.* 2002;10:5-15.
31. Fife CE, Buyukcakir C, Otto GH, et al. The predictive value of transcutaneous oxygen tension measurement in diabetic lower extremity ulcers treated with hyperbaric oxygen therapy: a retrospective analysis of 1,144 patients. *Wound Repair Regen.* 2002;10:198-207.
32. Padberg F, Back T, Thompson P, Hobson R. Transcutaneous oxygen (TcPO2) estimates probability of healing in the ischemic extremity. *J Surg Res.* 1996;60:365-369.
33. Ovington LG. Dressings and adjunctive therapies: AHCPR guidelines revisited. *Ostomy Wound Manage.* 1999;45(suppl 1A):94S-106S.
34. Health Care Financing Administration. Coverage Issues Manual 35-10, Hyperbaric Oxygen Therapy [transmittal No. 112]. Washington, DC: Health Care Financing Administration; 1999.
35. Strauss MB, Bryant BJ, Hart GB. Transcutaneous oxygen measurements under hyperbaric oxygen conditions as a predictor for healing of problem wounds. *Foot Ankle Int.* 2002;23:933-937.
36. Sheffield PJ. Tissue oxygen measurements with respect to soft tissue wound healing with normobaric and hyperbaric oxygen. *HBO Rev.* 1985;6:18-43.
37. Mustoe TA, Pierce GF, Thomason A, Sporn M, Gramates PH, Deuel TF. Accelerated healing of incisional wounds in rats induced by transforming growth factor-beta. *Science.* 1987;237:1333-1335.
38. Mustoe TA, Landes A, Cromack DT, et al. Differential acceleration of healing of surgical incisions in the rabbit gastrointestinal tract by platelet-derived growth factor and transforming growth factor, type beta. *Surgery.* 1990;108:324-330.

#### Announcement

**T**he *Archives of Surgery* will give priority review and early publication to seminal works. This policy will include basic science advancements in surgery and critically performed clinical research.