

# Visual loss as a late complication of carbon monoxide poisoning and its successful treatment with hyperbaric oxygen therapy

*Dilaver Ersanli<sup>a</sup>, Senol Yildiz<sup>b</sup>, Erdem Togro<sup>k</sup>, Hakan Ay<sup>b</sup>, Tauland Qyrdedi<sup>b</sup>*

<sup>a</sup> Gülhane Military Medical Academy, Haydarpaşa Training Hospital, Department of Ophthalmology, Kadıköy/İstanbul, Turkey

<sup>b</sup> Gülhane Military Medical Academy, Haydarpaşa Training Hospital, Department of Underwater and Hyperbaric Medicine, Kadıköy/İstanbul, Turkey

<sup>c</sup> Gülhane Military Medical Academy, Haydarpaşa Training Hospital, Department of Neurology, Kadıköy/İstanbul, Turkey

## Summary

**Purpose:** To present recovery from vision loss due to CO poisoning with Hyperbaric Oxygen (HBO) therapy in two patients.

**Methods:** Two female patients developed visual deterioration after carbon monoxide (CO) poisoning and were treated with hyperbaric oxygen therapy (HBO). Clinical examination, including visual acuity assessment, visual field examination and visual evoked potentials (VEPs) before and after the HBO therapy were performed.

**Results:** In Case 1 the visual loss started on the third day with visual acuity at the level of perception of hand movements at 10 cm in the right eye and finger count at 10 cm in the left eye. The visual evoked potentials (VEPs) had low amplitudes and prolonged (128 msec bilaterally) latencies (implicit times). After 48 sessions and 52 days of HBO therapy, the visual acuity became 0.2 in the right eye and 0.15 in the left eye. Visual field examination revealed homonymous right lower quadrant anopsia. The VEPs also improved.

In Case 2 the visual acuity was 0.2 in the right eye and 0.1 in the left eye on the 6th day following the accident when the patient was admitted for treatment. The VEP latencies were within normal limits. After 36 days and 35 sessions of HBO therapy, the visual acuity became 0.7 on both eyes. The visual fields completely normalised. The VEP latencies in this case also became shorter.

**Conclusion:** It appears that the adverse effects of CO poisoning continue to progress during the late period and we believe that HBO treatment in this period may still be effective and will prevent some of the neurological sequelae such as visual loss from becoming permanent. Clinical, neurological, neuropsychological, visual outcome seems to be favourable even if HBO treatment started as late as 6 or 8 days after the exposure to CO.

**Key words:** carbon monoxide poisoning; visual loss; hyperbaric oxygen therapy (HBO)

## Introduction

Death or permanent neurological damage including blindness or severe visual disability due to carbon monoxide (CO) poisoning is frequent in Turkey and presents a serious health problem in such developing and developed countries, causing injury and death. These intoxications can be accidental or due to suicidal or homicidal intent. Visual symptoms due to CO poisoning are not encountered very frequently in routine clinical practice. Two cases have been reported by Quattrococo et al. and Katafuchi et al. [1, 2]. Permanent damage is known to occur in untreated cases. Spontaneous recovery in the late period (as late as 18 months) after the CO poisoning in an untreated case has also been reported [3].

Other neural and neuropsychiatric manifestations of CO poisoning are encountered more frequently and include non-focal alteration in mental state, seizures, amnesia, apraxia, agnosia, parkinsonism, incontinence, and peripheral neuropathy [4].

CO is a colourless, odourless, tasteless gas and is produced by the incomplete combustion of carbon-containing materials. Large-scale public education campaigns on the safe operation of appliances containing combustion engines and other high-risk components, heaters, fireplaces, and engines are needed for the prevention of carbon monoxide poisoning.

During the CO intoxication, carboxyhaemoglobin (COHb) is created. Neurovascular autoregulation is disrupted due to the toxic damage and the hypoxia that occurs because of this molecule. Mitochondria in the cells are affected and the endothelial membrane of capillaries is damaged [5]. Some areas in the central nervous system are especially vulnerable to tissue hypoxia and the hypotension due to these mechanisms. These areas include the "watershed" areas and the basal ganglia where anastomoses are relatively few. These areas are affected to different degrees and transient or permanent damage may occur. The neurological sequelae that occur after the intoxications are probably due to these mechanisms. Neuropathological findings may include demyelination of cerebral

cortex and neuronal death in the cortex, hippocampus, substantia nigra and globus pallidus [6].

The most effective treatment of CO poisoning is hyperbaric oxygen (HBO) treatment [7, 8]. The usual advice is to give this treatment within the first six hours. Unfavourable cognitive and behavioural sequelae (problems with memory, attention or concentration, and affect) can occur immediately after exposure to CO and persist, or these complications may be delayed. Persisting neuropsychological deficits were described in 26% of patients as late as one year after poisoning [9].

We report here the favourable outcome of two cases of CO poisoning whose HBO-treatment had an adequate but relatively late start, on the 6<sup>th</sup> day (in Case 1) and the 8<sup>th</sup> day (in Case 2) after accident.

## Case reports

### Case 1

The patient, a 34-year old female with no history of previous neurological or other systemic disease was discovered unconscious by her husband half an hour after she went to the bathroom to take a bath. She was taken to the nearest hospital where she was given normobaric oxygen by mask after which she regained consciousness. Oxygen inhalation at atmospheric pressure was continued intermittently for two more days. The patient had no visual complaints on the first three days after the accident. On the third day, she started to complain of memory problems and on the same day started also to complain of blurring of vision. Later on, nausea, vomiting, headache and visual problems gradually increased. She was referred to our hospital on the eighth day of the incident.

On examination before the HBO treatment, she was awake, alert and oriented to person, place, time and situation. She followed commands easily without hesitation. Her speech was clear with no dysarthria. The fluency, speed and volume of her speech was normal with normal repetition and comprehension. The neurological routine examination, including cranial nerve function, motor system examination, reflexes, sensory and cerebellar evaluations were within normal limits. Her hearing was within normal limits. On the inspection of her gait; her posture was normal but she had difficulty in walking due to nausea and vertigo. On ophthalmological examination, the adnexia and refractive media (ie, lens and cornea) were normal, her ocular eye movements in all directions were normal. The pupils were equal, 3.5–4 mm in diameter round, reactive to light with no afferent defect. The visual acuity was at the level of perception of hand movements at 10 cm in the right eye and finger count at 10 cm in the left eye. On fundoscopy, the nasal margins of both optic discs appeared blurred, suggesting mild oedema. Visual field examination could not be tested because of low visual acuity. Initial Cranial CT and MR at the acute stage revealed no pathological findings.

Pattern reversal visual evoked potentials (VEPs) were recorded with an EP apparatus (Medelec MS 92A) and a Toshiba video monitor. During the procedure a checkerboard pattern was used and each eye was evoked separately by closing the other in sequence. (3 reversals per second) The mean value of 300 responses were used to obtain cortical response and each evaluation was performed twice. The potentials obtained had nearly extinguished amplitudes, 1.0  $\mu$ V on the right side and 0.9  $\mu$ V on the left side,

and their latencies, as far as readable, were found to be prolonged up to 128 msec bilaterally (our laboratory's normal upper limits for both eyes: 110.5.ms; 95 percentile boundary established for normals.).

The visual fields were obtained by examination with a Synemed Field Trend v1.2 apparatus. This examination revealed the impression of total visual field loss on both eyes.

Hyperbaric oxygen therapy (HBO) was planned upon arrival of this case at our unit on the eighth day following the incident at 2.4 ATA (Absolute atmosphere pressure) for 90 minutes (3 cycles of 25 min hyperbaric 100% oxygen with a mask followed by 5 minutes of hyperbaric normal air from the chamber) HBO therapy was carried out in a hyperbaric chamber (Galeazzi, Italy). The 100% oxygen was given via an oxygen mask. HBO was completed after 48 sessions, which was 53 days after the initiation of the therapy and 61 days after the accident. Two sessions were done on the first day and afterwards the therapy was continued with one session per day on weekdays. The patient's nausea and vomiting disappeared after the first session. The patient reported some improvement in visual acuity. By the twenty-fifth session, the appearance of oedema on the nasal margins of both optic discs had disappeared. At this point, the visual acuity was finger counting at 2 meters for the right eye and finger counting from 1.5 meters on the left. At the end of the 48th session, the visual acuity was found to be 0.2 for the right eye and 0.15 on the left with the Snellen chart. The patient's vision progressively improved during the HBO treatment from the beginning. The VEP evaluation (the same protocol as at the beginning) repeated at the end of the treatment revealed improved signal amplitudes (3.3  $\mu$ V and 3.9  $\mu$ V respectively) and shorter implicit times (118.4 msec on stimulation of the right eye, 120.6 msec on stimulation of the left eye) The visual field examination showed a homonymous right lower quadrant anopsia [Figure 1]

### Case 2

The patient, a 32-year old female with no history of previous neurological or other systemic disease was discovered unconscious by her husband in the bathroom. She was taken to the nearest hospital where she was given normobaric oxygen by mask after which she regained consciousness. She was referred to our hospital on the sixth day of the incident with visual complaints. She reported that she could see almost nothing. She also reported not

being able to remember the first four days after the incident. On examination, she was awake, alert and oriented to person, place, time and situation. She appeared slow and hesitant at first in answering questions and following commands, but eventually answered all questions and followed all commands correctly. Her speech was clear and fluent with no dysarthria and normal comprehension. Her hearing was within normal limits. Her memory for the previous two days on admission to our unit was intact; yet there was a persistent amnesia for the first four days following the incident). On ophthalmological examination, the adnexia and refractive media (ie, lens and cornea) were normal, ocular eye movements in all directions were normal. The pupils were equal, 3.5–4 mm in diameter, round, reactive to light with no relative afferent defect. Fundoscopy was normal. Visual acuity was 0.2 for the right eye and 0.1 on the left with the Snellen chart. The rest of the neurological examination, including cranial nerve function, motor system examination, reflexes, sensory and cerebellar evaluations was within normal limits. Her gait and posture was normal. Initial Cranial MR at the acute stage was normal.

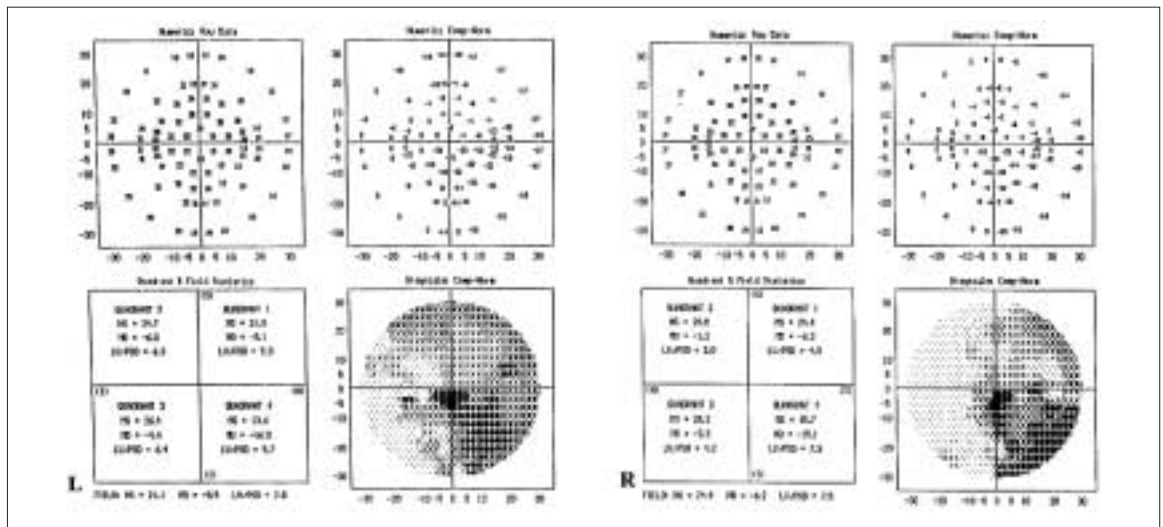
VEPs were recorded with EP apparatus Medelec Synergy with the same protocol as in Case 1. The potentials obtained had low amplitudes. The amplitude of the potential obtained from stimulating the right eye was 2.9  $\mu$ V and the amplitude of the potential from stimulating the left eye was 2.1  $\mu$ V. The latencies were found to be in the normal range – 111.0 msec for the potential from

stimulating the right eye and 111.5 msec for the potential from stimulating the left eye. The visual field examination was performed with the Marco Technologies MS-30 apparatus. The initial visual field examination on admission showed an almost total visual field restriction of the left eye [Figure 2, A] and heterogeneous, irregular visual field restrictions on the right [Figure 2, C].

Hyperbaric oxygen therapy (HBO) was planned for the patient on the sixth day after the accident on admission to our unit at 2.4 ATA for 120 minutes (3 cycles of 35 min hyperbaric 100% oxygen with mask followed by 5 min of hyperbaric normal air from the chamber). As in case 1, HBO therapy was carried out in a hyperbaric chamber (Galeazzi, Italy) and 100% oxygen was given via oxygen mask. HBO was completed after 35 sessions, which was 36 days after the initiation of the HBO therapy and 42 days after the accident. Two sessions were done on the first treatment day and afterwards they were continued with one session per day on weekdays. Vision progressively improved during the HBO treatment right from the beginning. At the end of the HBO therapy, the visual acuity was found to be 0.7 for both eyes with the Snellen chart. The VEPs repeated at the end of the treatment showed improved amplitudes (the left eye had increased from 2.1  $\mu$ V to 6.7  $\mu$ V and the right eye from 2.9  $\mu$ V to 8.0  $\mu$ V) and shorter implicit times (from 111.5 msec to 108.0 msec for the left eye and from 111.0 to 103.5 msec on the right) The visual field examination showed a complete recovery in both eyes [Figure 2 B, D].

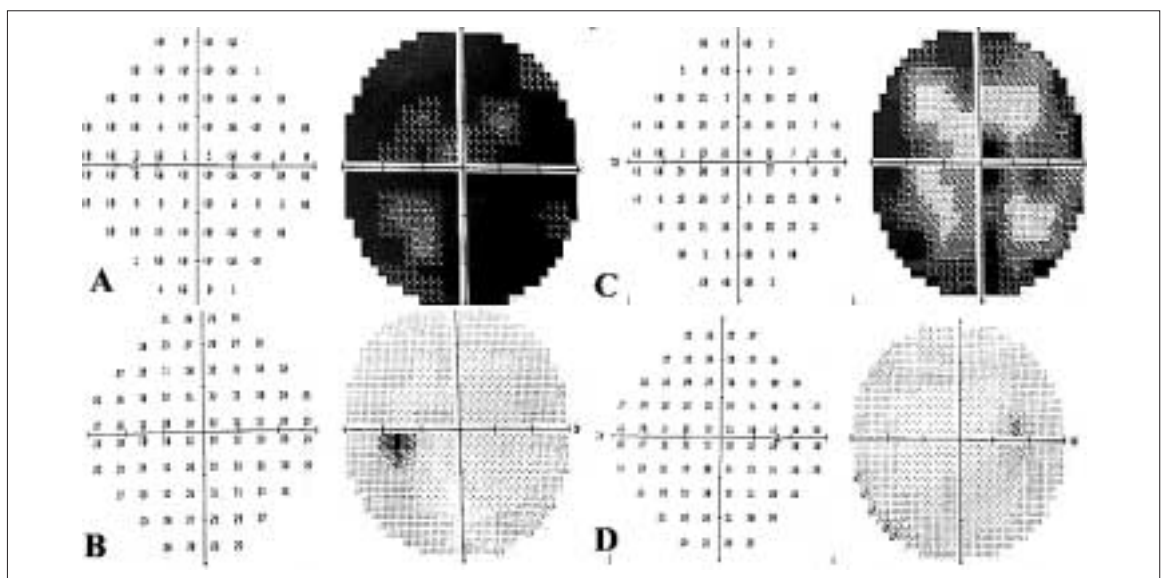
**Figure 1**

Visual field examination of Case 1 after HBO treatment (L: left eye, R: right eye). Note: No visual field examination could be carried out due to low visual acuity before HBO therapy.



**Figure 2**

Visual field examination of Case 2 before and after HBO treatment. A: Left Eye before therapy B: Left Eye after therapy C: Right Eye before HBO therapy D: Right Eye after HBO therapy



## Discussion

The fact that oxygen is useful in the treatment of CO poisoning was first established in 1868 and 100% oxygen has been the standard treatment for this condition for more than a century. HBO was first used in clinical intoxications in 1942 [10]. After exposure; CO binds to haemoglobin in the blood and replaces the oxygen, thus binding to a number of intracellular proteins, causing lipid peroxidation in the brain, depleting ATP in the tissues and eventually leading to apoptosis in the brain tissue. COHb levels can be rapidly reduced with HBO therapy in the acute period. The dissociation of CO from cytochrome  $a_3$  is accelerated, a more rapid return to normal levels of the cytochrome redox state is induced, brain lipid peroxidation is reduced; intracranial hypertension is prevented or reduced eventually and with the increase of intracellular oxygen cell and tissue damage can be prevented [5]. It has been shown that HBO treatment is more effective than normobaric treatment and fewer neurological sequelae are reported in the first year following the incident [8, 9]. Studies done in rats have shown that on the third day after poisoning there is a mild cellular loss in the brain; this increases on the seventh day and becomes permanent on the twenty-first day with the development of necrosis [5]. Most published data strongly suggest that when HBO is given to individuals with moderate or severe CO poisoning within approximately six hours after exposure to CO, it not only induces a more rapid recovery, but also reduces the most-feared complications such as persistent or delayed neurological sequelae [11]. For these reasons, it is very important to start with the treatment as soon as possible. HBO treatment is advised in the early period after intoxication even in patients without loss of consciousness [11].

On the other hand, HBO treatment has been shown to be effective in a number of neurological and ophthalmologic conditions other than those caused by CO poisoning and decompression sickness. These include visual field defects due to chorioretinal circulation disturbance, retinal artery occlusion and ischaemic optic neuropathy [12].

We report two cases with late onset visual loss and their HBO treatment. Our results suggest that clinical, neurological, neuropsychological. visual outcome may be favourable in some cases even if HBO treatment is started as late as 6 or 8 days after exposure to CO. An additional interesting fact with these two patients is the late onset of the visual loss. This loss was treated to some extent successfully with HBO treatment.

Although central nervous system involvement due to CO poisoning is relatively frequent, visual complaints are relatively rare in clinical practice. We have seen only two patients with this complaint in our hospital since 1990, both of which are reported here. Quattrococo et al. have reported a case

of cortical blindness due to CO poisoning in 1987 that occurred 7 days after the acute CO poisoning with denial of blindness, visual confabulation and slight loss of retentive memory. This patient's visual complaints are reported to have cleared within 6 days while the patient continued to have diffuse slowing of the electroencephalographic pattern. The CT which was within normal limits displayed 2 weeks later a faint, diffuse hypodensity of the white substance, marked in the occipital region. This finding was reported to disappear in the control CT taken 80 days later. (1). Katafuchi et al. reported a 3-year old boy with persistent cortical blindness following acute CO poisoning. The CT and VEPs at the early stage, normal initially, showed leukomalacia in the CT scan and pathology in the VEPs (2). Öner et al. have reported their 20-month follow-up of another case with CO poisoning in 2002. This case also is reported to have been followed-up with visual field examinations, visual acuity tests and VEPs. Initial cranial MR is reported to have shown areas consistent with hypoxia in the region of the basal ganglia. The bilateral visual loss which is reported to have developed in this subject following the poisoning persisted for 18 months after which it improved to left lower quadrant anopsia [3].

The probable site of the lesion in such patients is at the cortical level, after corpus geniculatum laterale, since pupillary responses were normal in both of our cases although vision was very low [13]. This is possible in cortical lesions, because of macular sparing. (A small central island in the visual field centre can be sufficient in order to preserve normal pupil reaction.) On the other hand, our patients may have had a transient cortical involvement which may have caused a temporary visual loss with some subcortical circuits remaining unimpaired. This is supported by the clinical findings in the cases reported by Quattrococo et al. [2] and Öner et al. [3] where the visual losses were temporary.

The papilloedema of the nasal margins that appeared and disappeared in Case 1 was probably due to a different pathology from the cortical lesion discussed above. This fundoscopic appearance probably resulted from a mild transient disruption of retinal circulation, which resolved within the first few days of the HBO therapy.

In both patients, the visual field examinations were worse in the left eyes. In this examination, it is a known fact that training and experience is important. In all our tests, the left eye was examined first. So, it may be that the patients were not well-adapted and trained for their visual field examinations of their left eyes. But, since the visual acuities of both subjects were also worse in their left eyes, we tend to think that the difference between the two visual fields were due to this factor and not due to the lack of training or experience.

Abnormalities of VEPs have been described in many disorders of the optic nerves, chiasm and the retrochiasmal visual pathways. Especially pathological processes along the optic pathways extending to the occipital cortex may cause abnormal VEP responses. Retinopathies, disorders of the optic nerve and chiasm, especially demyelinating processes including those seen in multiple sclerosis, neuromyelitis optica etc., some toxic neuropathies and some tumours are typical examples [14]. On the other hand, the reliability of VEPs in the work-up of cortical and other retrochiasmal lesions is questionable. Different studies in the previous two decades have ended with inconsistent results. Celesia et al. have tested 50 patients with verified ischaemic areas in their occipital or temporoparietal lobes and have concluded that VEPs are not sufficiently sensitive to be useful in clinical practice, while visual field and perimetry were much more helpful [14, 15]. As the main pathology in CO poisoning, the condition discussed in this article, is probably retrochiasmal, the diagnostic sensitivity of VEPs in this condition may be somewhat lower than desired.

He et al. have reported that lengthening of the VEP latencies may be accepted as a criterion for HBO treatment, but Emerson et al. have discussed that this finding is not very specific and sensitive in mild and moderate CO poisoning and thus should not be used as a screening tool for treatment decision making [16, 17]. In this study VEPs were used along with other diagnostic tests for several reasons. Firstly they were used to rule out other clinical conditions (eg, acute ischaemic optic neuropathy or some psychiatric conditions, where VEP implicit time is not prolonged). Secondly we intended to find out what changes could be detected in the VEPs during the recovery process. The recovery was demonstrated with the clinical findings and the results of the visual field and acuity tests, thus VEPs were not the only criteria used in our evaluation.

An interesting implication of this report is that in some CO intoxications no visual complaints may be present in the acute period and neural dysfunction may develop in the following days. In Case 1 visual disturbances were not present at initial admission to the first hospital she was referred to. Another interesting finding is that in these patients HBO treatment seems to have been effective even in the later period and some of the symptoms were reversible. In Case 1, memory defects developed on the third day and visual problems

developed on the fifth day despite normobaric oxygen being given in the first two days by mask. In Case 2 memory defects developed immediately after exposure to CO. Visual problems may have also started immediately after this exposure, but this could not be confirmed because of the case's loss of memory for the first four days after the accident. She received normobaric oxygen once before coming to our unit. This implies that the pathological process is continuing in the brain cells. In cases reported in literature, this progressive pathological process has also been demonstrated [1]. The HBO treatment, which was initiated on the eighth day in Case 1 and on the sixth day in Case 2 stopped this process and reversed the visual loss partially. The shortening of the VEP latency after treatment demonstrated in both our cases, accompanying clinical improvement in visual acuity indicates some improvement in the function of brain cells. The visual field defects along with reactive pupils in these patients seem to point to a transient left temporal and/or parietal pathology or functional disruption.

The Committee report of Undersea and Hyperbaric Medical Society advises at least two sessions of HBO treatment in patients with persistent neurological dysfunction, and subsequent treatments if needed. The committee also points out that the cost of HBO in this condition is modest and lists it as the primary mode of therapy for this condition [18].

It seems evident that the adverse effects of CO poisoning continue to progress, at least in some cases, during the late period. We believe that HBO treatment in this period may still be effective and may prevent some of the neurological, neuropsychological, and visual sequelae from becoming persistent. We also believe that it is better to apply HBO treatment which is recommended, relatively safe and cheap, rather than taking any risk of a permanent disability.

---

*Correspondence:*

*Dr. Senol Yildiz*

*Deniz ve Sualtı Hekimi*

*GATA Haydarpaşa Eğitim Hastanesi*

*Deniz ve Sualtı Hekimliği Servisi 81010*

*Kadıköy-İstanbul*

*Turkey*

*E-Mail: senolyildiz@hotmail.com /*

*syildiz@gata.edu.tr*

---

## References

- 1 Katafuchi Y, Nishimi T, Yamaguchi Y, Matsuishi T, Kimura Y, Otaki E, et al. Cortical blindness in acute carbon monoxide poisoning. *Brain Dev* 1985;7:516-9.
- 2 Quattrocchio G, Leotta D, Appendino L, Tarenzi L, Duca S. A case of cortical blindness due to carbon monoxide poisoning. *Ital J Neurol Sci* 1987.
- 3 Oner FH, Karaca A, Bajin MFS. Karbon Monoksit intoksikasyonunda göz bulguları. (Ophthalmological symptoms in carbon monoxide poisonings) *T Oft Gaz* 2002;32:856-8.
- 4 Garland A, Pearce J. Neurological complications of carbon monoxide poisoning. *Q J Med* 1967;36:445.
- 5 Piantadosi CA, Zhang J, Levin ED, Folz RJ, Schmechel DE. Apoptosis and delayed neuronal damage after carbon monoxide poisoning in the rat. *Exp Neurol* 1997;147:103-14.

- 6 Lapresle J, Fardeau M. The central nervous system and carbon monoxide poisoning. In the progress in Brain Research (Bahr H, Ledingham IM, eds.) Elsevier, Amsterdam, 1967;24:31-74.
- 7 Camporesi EM. Chairman: Hyperbaric oxygen therapy: a committee report. Bethesda MD: Undersea and Hyperbaric Medical Society. 1996.15-21.
- 8 Weaver LK, Hopkins RO, Chan KJ, Churchill S, Elliott CG, Clemmer TP, et al. Hyperbaric oxygen for acute carbon monoxide poisoning, *N Engl J Med* 2002;347:1057-67.
- 9 Thom SR, Taber RL, Mendiguren II, Clark JM, et al. Delayed neurological sequelae after carbon monoxide poisoning. Prevention by treatment with hyperbaric oxygen. *Ann Emerg Med* 1995;24:474-80.
- 10 Weaver LK. Hyperbaric oxygen in carbon monoxide poisoning. *BMJ* 1999;23:1083-4.
- 11 Hopkins RO, Weaver LK, Larson - Lohr V, Howe S. Loss of consciousness in not required for neurological sequela due to co poisoning. *Undersea Hyper Med* 1995;22:14.
- 12 Jain KK. Hyperbaric oxygen and opthalmology. In: *Textbook of Hyperbaric Medicine*, 3rd revised edition Jain KK (ed). Seattle-Toronto-Bern-Göttingen: Hogrefe & Huber Publishers, 1999; 504-18.
- 13 Pearlman AL. The central visual pathways. in *Adler's physiology of the eye clinical application*. Eds: Moses RA, Hart WM, Jr. Mosby Company, 8th edition, St Louis, 1987.
- 14 Celesia GG. Visual Evoked Potentials in Clinical Neurology. in *Electrodiagnosis in Clinical Neurology*, Aminoff M.J. (Ed.), pp. 467-89. Churchill Livingstone, Third Edition, New York, 1992.
- 15 Celesia GG, Meredith JT, Pluff K. Perimetry, visual evoked potentials and visual evoked spectrum array in homonymous hemianopsia. *Electroencephalography and Clinical Neurophysiology* 1982;54:121.
- 16 He F, Liu X, Yang S, et al. Evaluation of brain function in acute carbon monoxide poisoning with multimodality evoked potentials. *Environ Res* 1993;60:213-26.
- 17 Emerson TS, Keiler J. Pattern shift visual evoked potential screening for HBO2 in mild-to-moderate carbon monoxide poisoning. *Undersea Hyper Med* 1998;25:27-32.
- 18 Hampson NB. Chairmen and editor. *Hyperbaric oxygen therapy: 1999 Committee report*. Kensington, MD: Undersea and Hyperbaric Medical Society, 1999.