

Practical Guidelines for the Prevention, Diagnosis, and Treatment of Osteonecrosis of the Jaw in Patients With Cancer

By Salvatore Ruggiero, DMD, MD, Julie Gralow, MD, Robert E. Marx, DDS, Ana O. Hoff, MD, Mark M. Schubert, DDS, MDS, Joseph M. Huryn, DDS, Bela Toth, DDS, MS, Kathryn Damato, RDH, MS, CCRP, and Vicente Valero, MD, FACP

Long Island Jewish Medical Center, New Hyde Park; Memorial Sloan-Kettering Cancer Center, New York, NY; University of Washington Medical Center; Seattle Cancer Care Alliance, Seattle, WA; University of Miami School of Medicine, Miami, FL; The University of Texas M.D. Anderson Cancer Center, Houston, TX; and University of Connecticut Health Center, Farmington, CT

Abstract

Purpose: This article discusses osteonecrosis of the jaw (ONJ) and offers health care professionals practical guidelines and recommendations for the prevention, diagnosis, and management of ONJ in cancer patients receiving bisphosphonate treatment.

Methods: A panel of experts representing oral and maxillofacial surgery, oral medicine, endocrinology, and medical oncology was convened to review the literature and clinical evidence, identify risk factors for ONJ, and develop clinical guidelines for the prevention, early diagnosis, and multidisciplinary treatment of ONJ in patients with cancer. The guidelines are based on experience and have not been evaluated within the context of controlled clinical trials.

Results: ONJ is a clinical entity with many possible etiologies; historically identified risk factors include corticosteroids, chemotherapy, radiotherapy, trauma, infection, and cancer. With emerging concern for potential development of ONJ in patients

receiving bisphosphonates, the panel recommends a dental examination before patients begin therapy with intravenous bisphosphonates. Dental treatments and procedures that require bone healing should be completed before initiating intravenous bisphosphonate therapy. Patients should be instructed on the importance of maintaining good oral hygiene and having regular dental assessments. For patients currently receiving bisphosphonates who require dental procedures, there is no evidence to suggest that interrupting bisphosphonate therapy will prevent or lower the risk of ONJ. Frequent clinical assessments and conservative dental management are suggested for these patients. For treatment of patients who develop ONJ, a conservative, nonsurgical approach is strongly recommended.

Conclusion: An increased awareness of the potential risk of ONJ in patients receiving bisphosphonate therapy is needed. Close coordination between the treating physician and oral surgeon and/or a dental specialist is strongly recommended in making treatment decisions.

Introduction

Background

Osteonecrosis of the jaw (ONJ) is a site-specific, osseous pathology that has been reported in the literature since the 19th century. Nonetheless, there is still no consensus definition for ONJ. It is very likely that ONJ is a clinical entity with many possible etiologies, and its pathogenesis is not well understood. Similar risk factors for osteonecrosis from other sites were suggested for ONJ (see sidebar “Historical Risk Factors for Osteonecrosis”).¹⁻⁵ Risk factors specific to ONJ include head and neck radiotherapy, periodontal disease, dental procedures involving bone surgery, edentulous regions, and trauma from poorly fitting dentures.²⁻⁶

Additional risk factors in cancer patients include the underlying malignancy, chemotherapy, corticosteroids, and systemic or regional infection.¹ Pancytopenia secondary to cancer and/or cancer treatment increases risk for infection and the potential for development of osteomyelitis.^{3,7} Vascular insufficiency due to thrombosis has been associated mechanistically with the development of ONJ.⁸ This event is a consequence of diminished arterial flow, increased intraosseous venous pressure, and osse-

ous hypoxia.⁹ Coagulopathies, typically manifested as thrombophilia or hypofibrinolysis, have been implicated as contributory factors,¹⁰ as has impaired blood flow secondary to edema or osteomyelitis.^{7,11,12} Potential pathogenic mechanisms for ONJ are detailed in Figure 1.^{1-4,8-35}

ONJ is most frequently linked with radiation-induced damage in patients with head and neck cancer or oral cancer. This condition is sometimes described as osteoradionecrosis.^{27,29,30} Osteonecrosis of the jaw in this setting may result from loss of osseous cellular elements as well as vascular damage that results in relative ischemia of the bone. The incidence and severity of radiation-induced osteonecrosis are dose, field, and fraction dependent; the incidence has been reported in a range from 0.4% to 8.2% in these patients, but can vary significantly among centers and among patients with multiple baseline risk factors.^{27,30}

Additionally, the jaws are subjected to risk factors for ONJ such as trauma from repeated dental procedures or infection. Whereas a single risk factor or condition may be associated with ONJ in a particular patient, studies have shown that coexistence

Historical Risk Factors for Osteonecrosis

Chemotherapy	Storage diseases
Cancer	Corticosteroids
Immunotherapy	Hypertension
Female sex/estrogen	Arthritis
Coagulation abnormalities	Blood dyscrasias
Infections	Vascular disorders
Smoking	Alcohol abuse
Edentulous regions	Malnutrition
Sickle-cell disease	Advanced age
Systemic lupus erythematosus	Gaucher's disease
Atmospheric pressure variations	Human immunodeficiency virus infection
Hemodialysis	Chronic inactivity
Hypersensitivity reactions	Hyperlipidemia and embolic fat
Hypothyroidism	Osteoporosis
	Neurologic damage

Data from Assouline-Dayana et al.¹

of multiple risk factors is associated with a significantly higher incidence of ONJ.^{2,3,5}

There is as yet no consensus definition of ONJ, and this is complicated by the lack of understanding of pathobiologic mechanisms. The clinical diagnosis of ONJ is usually made on the basis of visual inspection (e.g., presence of exposed bone) and/or radiographic appearance. The bone lesions of ONJ may appear less or more radiodense than unaffected bone, providing a radiographic appearance similar to that observed in bone metastasis. The location of the lesion(s) tends to favor the mandible over the maxilla; the reason for this is not clear.

Reports of ONJ in Patients Treated With Bisphosphonates

Reports of ONJ in cancer patients treated with both oral and intravenous (IV) bisphosphonates have recently been published (Table 1).^{15,16,31,32,36-45} As of December 2004, more than 200 cases of ONJ have been reported. The majority of publications are letters to the editor or case report series. The first report of a series of ONJ cases associated with bisphosphonates was published in a letter by Marx in 2003, which described 36 cases of ONJ.³² The largest number of cases was reported by Ruggiero et al,³¹ who described 63 cases of ONJ from their oral surgery practice between February 2001 and November 2003. These patients were predominantly female (71%) and typically presented with bone pain, nonhealing extraction sockets, or exposed bone, primarily in the mandible (63%). Nearly all patients (86%) had had previous dental procedures. In the majority of cases, pain associated with exposed bone was controlled successfully using a nonsurgical approach consisting of oral sys-

temic antibiotics and 0.12% chlorhexidine gluconate antiseptic-containing oral rinses. Aggressive surgical intervention was counterproductive and often exacerbated bone exposure. ONJ has been reported in patients with a variety of tumor types, including multiple myeloma and breast, prostate, and thyroid cancer. Overall, reports of ONJ have been most common in patients with multiple myeloma. Although the majority of ONJ cases were reported in patients with cancer, 11% of patients were receiving oral bisphosphonates for osteoporosis.³¹

In the cases reported to date, most patients were receiving long-term chemotherapy and many were receiving short-term intermittent corticosteroid therapy with concomitant bisphosphonate therapy for cancer and symptom management. However, given the growing number of cases of ONJ in patients treated with bisphosphonates, it is important to recognize the potential risk that this class of drugs may present in the development of ONJ.

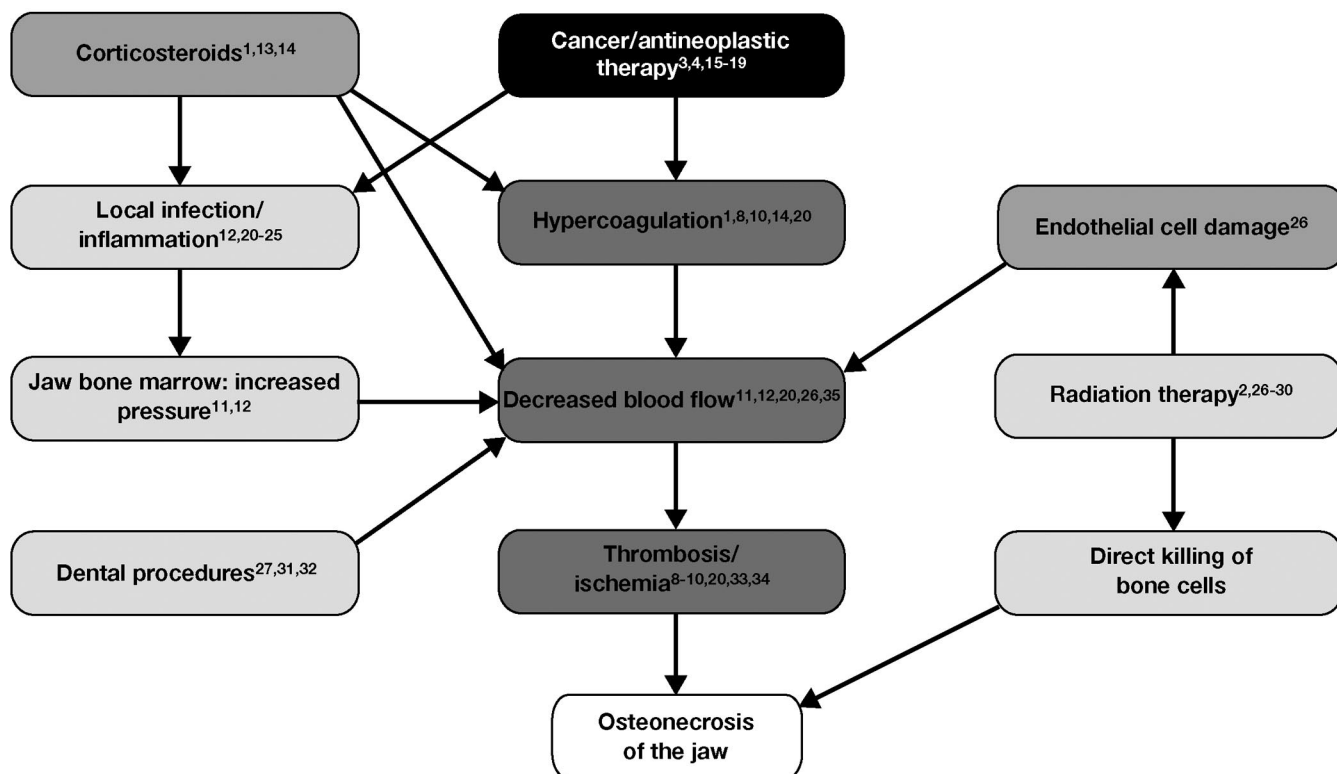
The potential mechanism by which bisphosphonates may be associated with the development of ONJ is unknown. It is clear that several issues need further clarification regarding ONJ in cancer patients treated with bisphosphonates. These include a clear case definition of ONJ with consensus diagnostic criteria and staging/severity measures. Additionally, further information is needed to provide a better understanding of the natural history of the disease, the impact of multiple risk factors on disease onset and time of onset, and appropriate treatment algorithms. Finally, the development of effective preventative measures and treatment algorithms would provide great clinical benefit for patients and health care providers. However, in the absence of further information on these issues, a multidisciplinary expert panel was convened to provide guidance to physicians on the identification, prevention, and treatment of ONJ based on current experience and understanding of ONJ in clinical practice.

Development of Practical Guidelines

To better understand the pathogenesis of ONJ and clinical management of patients with ONJ, an expert multidisciplinary panel representing oral and maxillofacial surgery, oral medicine/oncology, endocrinology, and medical oncology convened in March 2004. The panel reviewed published literature and clinical evidence to identify risk factors for ONJ and to develop clinical guidelines for the prevention, early diagnosis, management, and multidisciplinary treatment of ONJ in patients with cancer receiving bisphosphonates. The following guidelines are the result of these deliberations.

The treatment guidelines developed by the panel were designed to apply to specific subsets of cancer patients. These include (1) patients initiating bisphosphonate therapy, (2) patients currently receiving bisphosphonate therapy who require dental intervention, and (3) patients with established ONJ. The panel's recommendations are presented to help guide health care providers in patient treatment. These recommendations are based

Figure 1. Potential mechanisms for the development of osteonecrosis of the jaw.^{1-4,8-35}



on expert opinion and experience in clinical practice and have not yet been evaluated in controlled clinical trials.

The benefit of bisphosphonates for the treatment of hypercalcemia of malignancy and the prevention of skeletal complications from bone metastases has been well established in several randomized, placebo-controlled trials.⁴⁶⁻⁵² Evidence linking bisphosphonates to ONJ consists primarily of spontaneous case reports from the Novartis (Basel, Switzerland) safety database, published case reports, and retrospective chart reviews. The panel found that it is not possible to accurately determine the incidence of ONJ from these reports because of inconsistencies across publications. Moreover, the evidence linking bisphosphonates to ONJ must be considered to rate as level V evidence (using ASCO level of evidence ratings). This is defined as evidence that is provided only from case reports and clinical examples.⁵³⁻⁵⁵ Prospective trials will be needed to evaluate the true incidence and clearly establish the causal factors related to ONJ in cancer patients.

Recommendations

Clinical Presentation and Diagnosis of ONJ

ONJ may remain asymptomatic for many weeks or months and is usually identified by its unique clinical presentation of exposed bone in the oral cavity. These lesions typically become symptomatic when sites become secondarily infected or if there is trauma to adjacent and/or opposing healthy soft tissues from irregular surfaces of the exposed bone. Signs and symptoms of

ONJ include localized pain, soft-tissue swelling and inflammation, loosening of previously stable teeth, drainage, and exposed bone. These symptoms most commonly occur at the site of previous tooth extraction or other dental surgical interventions, but may occur spontaneously. Some patients may present with atypical complaints such as “numbness,” the feeling of a “heavy jaw,” and various dysesthesias. Objective signs that may occur before frank clinical presentation of ONJ include a sudden change in the health of periodontal or mucosal tissues, failure of the oral mucosa to heal, undiagnosed oral pain, loose teeth, or soft-tissue infection. The clinical presentation of ONJ represents a spectrum of symptoms, signs, and severities, from relatively asymptomatic to more severe lesions.

If osteonecrosis is suspected, panoramic and tomographic imaging may be performed to rule out other causes (e.g., cysts, impacted teeth, or metastatic disease). The radiographic signs suggestive of ONJ most often involve osteolysis consistent with bone loss. Intraoral films can also be used to provide better detail and demonstrate more subtle bone changes. However, radiographic alterations seen in patients with ONJ treated with bisphosphonates are often subtle in earlier stages of the disease and may be difficult to detect. Initially, minimal detectable radiographic changes are observed. Over time, as surface bone breaks down, radiographs eventually show radiolucent changes.

Tissue biopsy should be performed only if metastatic disease is suspected. If a biopsy is warranted, microbial cultures (aerobic and anaerobic) are suggested to identify pathogens with the

Table 1. Cases of osteonecrosis of the jaw* in cancer patients treated with bisphosphonates reported in the literature

Author	Year	No. of Patients	Publication Type	Underlying Disease(s)	Bisphosphonate(s)	Risk Factor(s)
Marx ³²	2003	36	Letter to the editor	HCM/multiple myeloma, n = 18 HCM/breast cancer, n = 17 Osteoporosis, n = 1	IV pamidronate, n = 24 IV zoledronic acid, n = 6 IV both zoledronic acid and pamidronate, n = 6	Dexamethasone, n = 22 Chemotherapy, n = 24 Radiotherapy, n = 4
Migliorati ³⁶	2003	5	Letter to the editor	Not reported	Pamidronate† IV zoledronic acid	Not reported
Ruggiero et al ³¹	2004	63	Article	Breast cancer, n = 20 Multiple myeloma, n = 28 Prostate cancer, n = 3 Other cancers, n = 4 Osteoporosis, n = 7	IV pamidronate, n = 34 IV zoledronic acid, n = 9 IV both zoledronic acid and pamidronate, n = 13 PO alendronate,‡ n = 6 PO risedronate, n = 1	Chemotherapy, n = 56
Estilo et al ³⁷	2004	13	Abstract	Breast cancer Multiple myeloma	Intravenous	Malignancy Corticosteroids, n = 9 Tobacco smoking, n = 6
Wang et al ¹⁶	2004	3	Case report	Breast cancer	IV pamidronate	Chemotherapy, n = 3 Diabetes mellitus and thalassemia, n = 1
Durie et al ³⁸	2004	46	Abstract	Multiple myeloma	IV zoledronic acid IV pamidronate	Corticosteroid use
Thakkar et al ³⁹	2004	14	Abstract	Multiple myeloma	IV zoledronic acid, n = 6 IV pamidronate, n = 8	Not reported
Schuster and Dymek ⁴⁰	2004	2	Abstract	Multiple myeloma	IV both zoledronic acid and pamidronate	Chemotherapy, n = 2 Thalidomide, n = 2 Autologous stem-cell transplantation, n = 1
Kut et al ⁴¹	2004	7	Abstract	Multiple myeloma	IV pamidronate and/or IV zoledronic acid	Corticosteroids, n = 7 Thalidomide, n = 3 Radiation, n = 2
Van Poznack et al ⁴²	2004	6	Abstract	Breast cancer	IV pamidronate or IV zoledronic acid	Not reported
Carter et al ⁴³	2005	5	Case report	Multiple myeloma, n = 2 Paget's disease, n = 3	IV pamidronate, n = 4 PO alendronate, n = 1	Tooth extraction, n = 4 Corticosteroids, n = 2 Chemotherapy, n = 1
Bagan et al ¹⁵	2005	10	Case report	Breast cancer, n = 6 Multiple Myeloma, n = 4	IV pamidronate, n = 4 IV zoledronic acid, n = 2 IV both zoledronic acid and pamidronate, n = 4	Chemotherapy, n = 10 Dexamethasone, n = 4 Thalidomide, n = 2
Melo and Obeid ⁴⁴	2005	1	Case report	Breast cancer	IV zoledronic acid	Malignancy, chemotherapy, hypertension
Purcell and Boyd ⁴⁵	2005	13	ADRAC report	Breast cancer, n = 5 Prostate cancer, n = 4 Multiple myeloma, n = 3 Osteoporosis, n = 1	IV pamidronate, n = 2 IV zoledronic acid, n = 10 PO alendronate, n = 1	Corticosteroids, n = 6 Chemotherapy, n = 4 Thalidomide, n = 1 Radiotherapy, n = 1

Abbreviations: HCM, hypercalcemia of malignancy; IV, intravenous; PO, oral; ADRAC, adverse drug reactions advisory committee (Australia).

* Some cases may be reported in more than one publication.

† Authors did not specify whether oral or IV pamidronate was used.

‡ One patient also received zoledronic acid.

potential to cause secondary infections. It is important to note that *Actinomyces* organisms are often seen microscopically or identified upon culture.

Potential Risk Factors for the Development of ONJ

Although this article focuses specifically on ONJ in cancer patients receiving bisphosphonate therapy, the precise inciting events that precipitate ONJ have not been clearly identified and probably vary. On the basis of reports from the literature, potential factors that may increase the risk of ONJ in patients receiving bisphosphonates include radiation therapy, dental extraction, infectious disease, dental trauma, concomitant therapy with corticosteroids, and chemotherapy. Occasionally, other concomitant risk factors may not be apparent. Further study of the potential relationship between ONJ and bisphosphonates is clearly needed.

Potential Preventive Measures Before Initiating IV Bisphosphonate Therapy

Before initiating IV bisphosphonate therapy, the panel recommends that all patients undergo a routine clinical dental exam including a panoramic jaw radiograph to detect potential dental and periodontal infections (Table 2). In general, as part of conservative preventative measures before initiating treatment, patients should be instructed to avoid any elective dental or surgical procedure that results in compromise of mucosal surfaces over bone or that results in exposure of bone that cannot completely heal before commencement of bisphosphonate therapy. If bisphosphonate therapy can be delayed briefly without the risk of a skeletal-related complication or complications secondary to hypercalcemia, teeth with a poor prognosis or in need of extraction should be extracted, other dental surgeries finished, and tissues allowed to heal completely before beginning bisphosphonate therapy. The benefits or risks of postponing bisphosphonate therapy in these clinical circumstances have not been systematically evaluated to date. Therefore, the decision to defer bisphosphonate treatment must be made by the treating oncologist in consultation with an oral maxillofacial surgeon or other dental specialist.

Prophylactic antibiotics are not indicated for routine dentistry before initiation of bisphosphonate therapy. However, antibiotics may be required for bacterial prophylaxis in patients at risk (e.g., those with an indwelling venous catheter or history of endocarditis, heart murmurs, artificial heart valves, etc.).

It is particularly important to educate patients regarding the necessity of excellent dental hygiene and timely symptom reporting. Patients who have begun bisphosphonate and antineoplastic therapy should have regularly scheduled hard- and soft-tissue oral assessments. The frequency of these assessments is left at the discretion of the treating physician or dentist, but could be as frequent as every 3 to 4 months, depending on the number of concomitant risk factors and general dental health.

Table 2. Anti-infective pharmacologic treatments recommended for patients with osteonecrosis of the jaw*

Treatment	Dose and Schedule
Antibacterials	
Penicillin VK	500 mg every 6 to 8 hours for 7 to 10 days, then bid for maintenance
Amoxicillin	500 mg every 8 hours for 7 to 10 days, then bid for maintenance
Patients with penicillin allergy	
Clindamycin	150 to 300 mg qid
Vibramycin	100 mg qd
Erythromycin ethylsuccinate	400 mg tid
Azithromycin	500 mg PO × 1 on day 1; 250 mg PO qd on days 2 to 5
Antifungals† (when required)	
Nystatin oral suspension	5 to 15 mL qid or 100,000 IU/mL
Mycelex troches (clotrimazole)	10 mg tid 5×/day for 7 to 10 days
Fluconazole	200 mg initially, then 100 mg qd
Antivirals‡	
Acyclovir	400 mg bid
Valacyclovir hydrochloride	500 mg to 2 g bid

Abbreviations: qid, four times daily; bid, twice daily; qd, once daily; tid, three times daily.

* Novartis (Basel, Switzerland), data on file.

† Other potential systemic antifungals include itraconazole or ketoconazole.

‡ Role of antivirals in the treatment of osteonecrosis of the jaw has not yet been established.

At a minimum, oncologists should perform a brief visual inspection of the oral cavity at baseline and at each follow-up visit to look for the presence of necrotic or exposed bone.

Recommended Dental Treatment for Patients Currently Receiving Bisphosphonate Therapy

The importance of maintaining excellent oral hygiene to reduce the risk of dental and periodontal infections should be emphasized to patients (see sidebar “Summary Guidelines”). Strategies for patient-specific oral care should be reviewed, reinforced, and modified according to existing clinical circumstances. Removable dentures should be examined for their potential to induce soft-tissue injury, especially tissue overlying bone, and adjusted if required. Routine dental cleanings should be performed carefully, with emphasis on avoiding soft-tissue injuries.

Endodontic (root canal) therapy is preferable to extractions when possible. It may be necessary to carry out coronal ampu-

tation with subsequent root canal therapy on retained roots to avoid the need for tooth extraction and the potential development of osteonecrosis. Elective jaw surgery, including dental implants, should be avoided during IV bisphosphonate therapy.

Treatment of Patients With ONJ

A consultation with an oral maxillofacial surgeon or dental oncologist is strongly recommended for the treatment of cancer patients who have developed ONJ (see “Summary Guidelines,” available online at www.jopasco.org). Close coordination between dental care and oncologic care is critical for optimal treatment of both ONJ and the underlying neoplastic disease.

Given that impaired wound healing has been reported in patients with ONJ, a nonsurgical approach may prevent further osseous involvement and expansion of established lesions. Only minimal surface bony debridement should be performed to reduce sharp or rough bone surfaces and thus decrease trauma to surrounding or opposing tissues (e.g., the lateral tongue when lingual mandibular bone is exposed). Biopsies are not recommended unless metastasis to the jaw is suspected. The benefit of a confirmed biopsy does not outweigh the risk of inducing further bone damage that could exacerbate the ONJ. If a biopsy is performed, both a portion of the area biopsied and a culture from the biopsy site should be submitted for microbial analysis because infection has been reported as a common complication of ONJ.

A removable appliance may be considered to cover and protect the exposed bone. Additionally, a protective stent may be of benefit for patients with exposed bone that causes trauma to adjacent soft tissues and for patients in whom the osteonecrotic site is traumatized repeatedly during normal oral function. Either a thin, vinyl, vacuformed mouth guard or thin acrylic stent may be used, provided that the device does not further traumatize the osteonecrotic site and that it can be maintained hygienically by the patient.

Well-fitting dentures can be worn if appropriate care is taken to minimize soft-tissue trauma or irritation. Minimizing trauma and irritation is especially important in patients receiving antibiotic therapy. Particular effort should be made to minimize irritation to tissues overlying bone. Patients should be instructed to clean and remove dentures at night.

Intermittent or continuous antibiotic therapy has been shown to be beneficial; cultures should be collected to determine the appropriate antibiotic therapy (Novartis, data on file). The goal of antibiotic therapy is to prevent secondary soft-tissue infection, pain, and osteomyelitis. At this time, the duration of antibiotic therapy and the benefits of oral antiseptic rinses have not been defined, but improved pain control and mucosal disease control have been observed anecdotally with this management strategy. The decision to treat with an antibiotic is a clinical judgment that should be made by an oral maxillofacial surgeon or other dental specialist in consultation with the treat-

ing physician/oncologist. Cultures should be collected to determine the appropriate antimicrobial intervention. These should include assessment of aerobic, anaerobic, viral, and fungal species. The type of culture to collect for testing depends on the concerns for specific types of microbes. Several antimicrobial pharmacologic therapies have been recommended (Table 2) and oral rinses of 0.12% chlorhexidine gluconate (Peridex, Zila Pharmaceuticals, Inc., Phoenix, Arizona) or minocycline hydrochloride (Arestin, Orapharma, Inc., Warminster, Pennsylvania) in periodontal pockets also may be useful (Novartis, data on file).

All patients should be monitored every 3 months, or more frequently if symptoms continue or worsen. If temporary soft-tissue liners are used, patients should be seen every 3 months to closely monitor any potential tissue damage.

In severe cases of ONJ, or if surgery is required in patients with established ONJ, stopping or interrupting bisphosphonate therapy may be considered. However, close coordination between the oral surgeon or dental specialist and the medical oncologist is recommended. Assessing the potential risk of further osteonecrosis versus the risk of skeletal complications or hypercalcemia of malignancy is important. Because bisphosphonates are incorporated into the mineral matrix of bone, it is unknown whether stopping bisphosphonate therapy provides benefit for managing ONJ. Therefore, the decision to stop bisphosphonate therapy must be coordinated between the treating oncologist and an oral surgeon. Antibiotics are appropriate during and after dental surgery in this patient population and should be continued postoperatively for at least 10 days (Table 2; Novartis, data on file). Experience has shown that penicillin remains the drug of choice and that a combination of penicillin and metronidazole is useful in patients with refractory infections. In patients with penicillin allergy, azithromycin or one of the quinolone antibiotics is a reasonable second-line drug. The choice of antimicrobials would depend on potential or known pathogens, relative tolerance by patients, and cost. It is not known whether drugs with known bone affinity are more effective in managing ONJ. Cultures taken from the extraction site at the time of oral surgery can provide guidance in making this decision.

In studies reported to date, hyperbaric oxygen has not been shown to be effective for treating ONJ and, therefore, is not recommended at this time. Placement of osseointegrated dental implants in patients being treated with bisphosphonates is also not recommended because their use may result in further damage to bone, thereby exacerbating osteonecrosis.

Treatment Recommendations From the International Myeloma Foundation

Additional information and treatment recommendations for patients with ONJ were circulated as part of *The Myeloma Minute*, a newsletter published by the International Myeloma Foundation (IMF).⁵⁶ The treatment recommendations en-

dorsed by the IMF are similar to those developed by this expert panel and are available online at http://myeloma.org/main.jsp?type=article&tab_id=1&menu_id=0&cid=1223.

Clinical Trials to Assess ONJ in Cancer Patients

A retrospective chart review is underway at The University of Texas M.D. Anderson Cancer Center (Houston, Texas) to obtain more information about the incidence, clinical features, and natural history of ONJ. More than 4,000 cancer patients being treated with IV bisphosphonates who have complete dental records have been identified. At the time of this writing, results from this study were expected in late 2005.

A large planned clinical trial of bisphosphonates has had protocol modifications to include monitoring for ONJ. Southwest Oncology Group (SWOG) 0307 is a large, randomized, prospective, comparative, phase III, 3-year trial of IV bisphosphonates (zoledronic acid, clodronate, and ibandronate) as adjuvant therapy for primary breast cancer with a planned enrollment of approximately 6,000 patients. Patients in this trial will undergo a dental exam at baseline and at study conclusion to evaluate for ONJ. Patients are expected to undergo standard dental examinations and care while on study. Any patient who develops ONJ while on study will be further evaluated for risk factors and clinical course. Additional trials to gain a better understanding of the incidence and clinical course of ONJ in cancer patients receiving bisphosphonate therapy are in the planning stages.

Conclusion

The skeletal complications that occur as a result of bone metastases can be associated with severe morbidity. Bisphosphonates are important medications that have significant benefits for cancer patients, reducing the morbidity from the serious skeletal complications of bone metastases. The overall risk of developing ONJ appears to be low, even in cancer patients who have concomitant suspected risk factors for ONJ, but the true incidence of this condition is not known. At this time, solely on the basis of the residual potential risk of developing ONJ, there is no evidence to support withholding bisphosphonate therapy in cancer patients at risk for developing skeletal complications

References

1. Assouline-Dayam Y, Chang C, Greenspan A, et al: Pathogenesis and natural history of osteonecrosis. *Semin Arthritis Rheum* 32:94-124, 2002
2. Assael L: New foundations in understanding osteonecrosis of the jaws. *J Oral Maxillofac Surg* 62:125-126, 2004
3. Schwartz HC: Osteonecrosis of the jaws: A complication of cancer chemotherapy. *Head Neck Surg* 4:251-253, 1982
4. Sung EC, Chan SM, Sakurai K, et al: Osteonecrosis of the maxilla as a complication to chemotherapy: A case report. *Spec Care Dentist* 22:142-146, 2002
5. Tarassoff P, Csermak K: Avascular necrosis of the jaws: Risk factors in metastatic cancer patients. *J Oral Maxillofac Surg* 61:1238-1239, 2003
6. Glueck CJ, Freiberg R, Gruppo R, et al: Thrombophilia and hypofibrinolysis: Pathogenetic etiologies of osteonecrosis. *J Invest Med* 45:243A, 1997 (abstr)
7. Wannfors K: Vascular changes after experimentally-induced inflammation in the mandible. *Int J Oral Maxillofac Surg* 18:79-82, 1989
8. Jones LC, Mont MA, Le TB, et al: Procoagulants and osteonecrosis. *J Rheumatol* 30:783, 2003

secondary to metastatic bone disease. The confirmed clinical benefit of bisphosphonates in cancer patients outweighs the potential risk of developing ONJ. Even if ONJ develops, it is manageable with conservative intervention, provided that patients are pain free and are functioning in a normal or near-normal manner. This may be true for cancer patients who have established risk factors for ONJ, because the overall risk of developing ONJ remains small even in patients with more than one risk factor. With increased awareness of this potential complication, it is expected that health care practitioners will be able to better identify, prevent, and manage ONJ, and thereby provide optimal care to their patients with cancer.

Acknowledgment

The authors would like to acknowledge the participation of Harry D. Harper, MD, as a member of the expert panel.

Authors' Disclosures of Potential Conflicts of Interest

Although all authors completed the disclosure declaration, the following authors or their immediate family members indicated a financial interest. No conflict existed for drugs or devices used in a study if they are not being evaluated as part of the investigation.

Authors	Employment	Leadership	Consultant	Stock	Honoraria	Research Funds	Testimony	Other
Salvatore Ruggiero					Novartis (A)			
Kathryn Damato			Novartis (A)					
Julie Gralow					Roche (A)	Novartis (A); Roche (A)		
Ana O. Hoff			Novartis (A)			Novartis (C)		
Joseph M. Huryn			Novartis (A)		Novartis (A)			
Robert E. Marx			Novartis (A)		Novartis (A)			
Mark M. Schubert			Novartis (A)		Novartis (A)			
Bela Toth			Novartis (A)		Novartis (A)	Novartis (A)		
Vicente Valero			Novartis (A)					

Dollar Amount Codes (A) < \$10,000 (B) \$10,000-99,999 (C) ≥ \$100,000 (N/R) Not Required

Corresponding author: Salvatore Ruggiero, DMD, MD, Long Island Jewish Medical Center, 270-05 76th Avenue, New Hyde Park, NY 11040, ruggiero@lij.edu.

9. Glueck CJ, Freiberg R, Gruppo R, et al: Thrombophilia and hypofibrinolysis: Reversible pathogenetic etiologies of osteonecrosis, in Urbaniak RJ, Jones JP (eds): *Osteonecrosis: Etiology, Diagnosis and Treatment*. Rosemont, IL, American Academy of Orthopaedic Surgeons, 1997, pp 105-110
10. Glueck CJ, Freiberg R, Glueck HI, et al: Hypofibrinolysis: A common, major cause of osteonecrosis. *Am J Hematol* 45:156-166, 1994
11. Sano T: Recent developments in understanding temporomandibular joint disorders—Part 1: Bone marrow abnormalities of the mandibular condyle. *Dentomaxillofac Radiol* 29:7-10, 2000
12. Wannfors K, Gazelius B: Blood flow in jaw bones affected by chronic osteomyelitis. *Br J Oral Maxillofac Surg* 29:147-153, 1991
13. Gebhard KL, Maibach HI: Relationship between systemic corticosteroids and osteonecrosis. *Am J Clin Dermatol* 2:377-388, 2001
14. Drescher W, Weigert WP, Bunger MH, et al: Femoral head blood flow reduction and hypercoagulability under 24 h megadose steroid treatment in pigs. *J Orthop Res* 22:501-508, 2004

15. Bagan JV, Murillo J, Jimenez Y, et al: Avascular jaw osteonecrosis in association with cancer chemotherapy: Series of 10 cases. *J Oral Pathol Med* 34:120-123, 2005
16. Wang J, Goodger NM, Pogrel MA: Osteonecrosis of the jaws associated with cancer chemotherapy. *J Oral Maxillofac Surg* 61:1104-1107, 2003
17. Mattano LA Jr, Sather HN, Trigg ME, et al: Osteonecrosis as a complication of treating acute lymphoblastic leukemia in children: A report from the Children's Cancer Group. *J Clin Oncol* 18:3262-3272, 2000
18. Arico M, Boccalatte MFP, Silvestri D, et al: Osteonecrosis: An emerging complication of intensive chemotherapy for childhood acute lymphoblastic leukemia. *Haematologica* 88:747-753, 2003
19. Winquist EW, Bauman GS, Balogh J: Nontraumatic osteonecrosis after chemotherapy for testicular cancer: A systematic review. *Am J Clin Oncol* 24:603-606, 2001
20. Glueck CJ, Freiberg R, Tracy T, et al: Thrombophilia and hypofibrinolysis: Pathophysiologies of osteonecrosis. *Clin Orthop Relat Res* 334: 43-56, 1997
21. Schwartz O, Pindborg JJ, Svenesingsen A: Tooth exfoliation and necrosis of the alveolar bone following trigeminal herpes zoster in HIV-infected patient. *Tandlaegebladet* 93:623-627, 1989
22. Shroyer JV III, Lew D, Abreo F, et al: Osteomyelitis of the mandible as a result of sickle cell disease: Report and literature review. *Oral Surg Oral Med Oral Pathol* 72:25-28, 1991
23. Pogrel MA, Miller CE: A case of maxillary necrosis. *J Oral Maxillofac Surg* 61:489-493, 2003
24. Mintz SM, Anavi Y: Maxillary osteomyelitis and spontaneous tooth exfoliation after herpes zoster. *Oral Surg Oral Med Oral Pathol* 73:664-666, 1992
25. Arikawa J, Mizushima J, Higaki Y, et al: Mandibular alveolar bone necrosis after trigeminal herpes zoster. *Int J Dermatol* 43:136-137, 2004
26. Bras J, de Jonge HK, van Merkesteyn JP: Osteoradionecrosis of the mandible: Pathogenesis. *Am J Otolaryngol* 11:244-250, 1990
27. Reuther T, Schuster T, Mende U, et al: Osteoradionecrosis of the jaws as a side effect of radiotherapy of head and neck tumor patients: A report of a thirty year retrospective review. *Int J Oral Maxillofac Surg* 32:289-295, 2003
28. Jereczek-Fossa BA, Orecchia R: Radiotherapy-induced mandibular bone complications. *Cancer Treat Rev* 28:65-74, 2002
29. Studer G, Gratz KW, Glanzmann C: Osteoradionecrosis of the mandibula in patients treated with different fractionations. *Strahlenther Onkol* 180:233-240, 2004
30. Sulaiman F, Huryn JM, Zlotolow IM: Dental extractions in the irradiated head and neck patient: A retrospective analysis of Memorial Sloan-Kettering Cancer Center protocols, criteria, and end results. *J Oral Maxillofac Surg* 61:1123-1131, 2003
31. Ruggiero SL, Mehrotra B, Rosenberg TJ, et al: Osteonecrosis of the jaws associated with the use of bisphosphonates: A review of 63 cases. *J Oral Maxillofac Surg* 62:527-534, 2004
32. Marx RE: Pamidronate (Aredia) and zoledronate (Zometa) induced avascular necrosis of the jaws: A growing epidemic. *J Oral Maxillofac Surg* 61:1115-1117, 2003
33. Glueck CJ, McMahon RE, Bouquot JE, et al: Heterozygosity for the Leiden mutation of the factor V gene, a common pathoetiology for osteonecrosis of the jaw, with thrombophilia augmented by exogenous estrogens. *J Lab Clin Med* 130:540-543, 1997
34. Kavadia-Tsatala S, Kolokytha O, Kaklamanos EG, et al: Mandibular lesions of vasooclusive origin in sickle cell hemoglobinopathy. *Odontology* 92:68-72, 2004
35. Glueck CJ, McMahon RE, Bouquot JE, et al: A preliminary pilot study of treatment of thrombophilia and hypofibrinolysis and amelioration of the pain of osteonecrosis of the jaws. *Oral Surg Oral Med Oral Pathol Oral Radiol Endod* 85:64-73, 1998
36. Migliorati CA: Bisphosphonates and oral cavity avascular bone necrosis. *J Clin Oncol* 21:4253-4254, 2003
37. Estilo CL, Van Poznak CH, Williams T, et al: Osteonecrosis of the maxilla and mandible in patients treated with bisphosphonates: A retrospective study. *J Clin Oncol* 23:750s, 2004 (suppl; abstr 8088)
38. Durie BGM, Katz M, McCoy J, et al: Osteonecrosis of the jaws in myeloma: Time dependent correlation with Aredia and Zometa use. *Blood* 104:216a, 2004 (abstr 756)
39. Thakkar SG, Isada C, Englund K, et al: Bisphosphonate therapy associated with an increased incidence of mandibular/maxillary osteomyelitis in multiple myeloma patients. *Blood* 104:313b, 2004 (abstr)
40. Schuster MW, Dymek JM: Oral cavity avascular bone necrosis: A newly recognized complication of intravenous (IV) bisphosphonate therapy in cancer patients. *Blood* 104:308b, 2004 (abstr)
41. Kut V, Mehta J, Tariman J, et al: Osteonecrosis of the jaw in myeloma patients receiving pamidronate or zoledronate. *Blood* 104:315b, 2004 (abstr)
42. Van Poznak CH, Estilo CL, Sauter MP, et al: Osteonecrosis of the jaw in patients with metastatic breast cancer. *Breast Cancer Res Treat* 88:S131-S132, 2004 (suppl 1; abstr)
43. Carter G, Goss AN, Doecke C: Bisphosphonates and avascular necrosis of the jaw: A possible association. *Med J Aust* 182:413-415, 2005
44. Melo MD, Obeid G: Osteonecrosis of the maxilla in a patient with a history of bisphosphonate therapy. *J Can Dent Assoc* 71:111-113, 2005
45. Purcell PM, Boyd IW: Bisphosphonates and osteonecrosis of the jaw. *Med J Aust* 182:417-418, 2005
46. Hultborn R, Gundersen S, Ryden S, et al: Efficacy of pamidronate in breast cancer with bone metastases: A randomized, double-blind placebo-controlled multicenter study. *Anticancer Res* 19:3383-3392, 1999
47. Lipton A, Theriault RL, Hortobagyi GN, et al: Pamidronate prevents skeletal complications and is effective palliative treatment in women with breast carcinoma and osteolytic bone metastases: Long term follow-up of two randomized, placebo-controlled trials. *Cancer* 88:1082-1090, 2000
48. Berenson JR, Lichtenstein A, Porter L, et al: Long-term pamidronate treatment of advanced multiple myeloma patients reduces skeletal events. *J Clin Oncol* 16:593-602, 1998
49. Major P, Lortholary A, Hon J, et al: Zoledronic acid is superior to pamidronate in the treatment of hypercalcemia of malignancy: A pooled analysis of two randomized, controlled clinical trials. *J Clin Oncol* 19:558-567, 2001
50. Rosen LS, Gordon D, Kaminski M, et al: Long-term efficacy and safety of zoledronic acid compared with pamidronate disodium in the treatment of skeletal complications in patients with advanced multiple myeloma or breast carcinoma: A randomized, double-blind, multicenter, comparative trial. *Cancer* 98:1735-1744, 2003
51. Saad F, Gleason DM, Murray R, et al: Long-term efficacy of zoledronic acid for the prevention of skeletal complications in patients with metastatic hormone-refractory prostate cancer. *J Natl Cancer Inst* 96:879-882, 2004
52. Rosen LS, Gordon D, Tchekmedyan NS, et al: Long-term efficacy and safety of zoledronic acid in the treatment of skeletal metastases in patients with nonsmall cell lung carcinoma and other solid tumors: A randomized, phase III, double-blind, placebo-controlled trial. *Cancer* 100:2613-2621, 2004
53. Hillner BE, Ingle JN, Berenson JR, et al: American Society of Clinical Oncology guideline on the role of bisphosphonates in breast cancer. *J Clin Oncol* 18:1378-1391, 2000
54. Berenson JR, Hillner BE, Kyle RA, et al: American Society of Clinical Oncology clinical practice guidelines: The role of bisphosphonates in multiple myeloma. *J Clin Oncol* 20:3719-3736, 2002
55. Kyle RA: Monoclonal gammopathy of undetermined significance: Natural history in 241 cases. *Am J Med* 64:814-826, 1978
56. International Myeloma Foundation: Myeloma minute: http://myeloma.org/myeloma/myeloma_minute.jsp?type=detail&id=560.