

# Hyperbaric oxygen does not accelerate latent *in vivo* prostate cancer: implications for the treatment of radiation-induced haemorrhagic cystitis

KIAN TAI CHONG\*‡, NEIL B. HAMPSON†, DAVID G. BOSTWICK¶, ROBERT L. VESSELLAS and JOHN M. CORMAN\*

\*Section of Urology and Renal Transplantation, †Center for Hyperbaric Medicine, Virginia Mason Medical Center, ‡Benaroya Research Institute at Virginia Mason, Seattle, WA, ¶Bostwick Laboratories, Richmond, VA, and §Department of Urology, University of Washington, Seattle, WA, USA

Accepted for publication 7 July 2004

## OBJECTIVE

To assess the effects of hyperbaric oxygen (HBO<sub>2</sub>; often used to treat haemorrhagic cystitis, a known side-effect after radiation therapy for prostate cancer and with the potential to induce tumour angiogenesis and stimulate latent recurrence) on indolent *in vivo* prostate cancer in a murine model.

## MATERIALS AND METHODS

Human prostate LNCaP cells were injected into 60 severe combined-immunodeficient mice; of these 24 (40%) did not develop palpable tumours after 6 weeks. They were randomized to undergo 20 sessions of either HBO<sub>2</sub> or normobaric air in standardized conditions, and observed for another 4 weeks

before the histological assessment of any palpable tumours that developed. Analysis of developed LNCaP tumours included tumour volume, microvessel density, MIB-1, p53, p27 and racemase staining intensity.

## RESULTS

HBO<sub>2</sub> was associated with less prostate tumour progression than normobaric air ( $P = 0.26$ ). During HBO<sub>2</sub> therapy, 10 mice remained free of palpable tumours, compared with seven controls ( $P = 0.30$ ). On evaluation during the 4 weeks after therapy, six mice treated with HBO<sub>2</sub> remained free of palpable tumours, vs eight of the controls ( $P = 0.17$ ). There was tumour invasion and necrosis in a two of six and four of the HBO<sub>2</sub> group during and after therapy, respectively, vs five and

seven of the controls. Tumour microvessel density, proliferative index, differentiation and apoptosis markers were similar in both groups.

## CONCLUSIONS

HBO<sub>2</sub> does not accelerate the growth of indolent prostate cancer in a murine model, suggesting that it does not increase the risk of residual prostate cancer reactivation when it is used to manage radiation-induced haemorrhagic cystitis in patients treated by pelvic radiotherapy for prostate cancer.

## KEYWORDS

prostate cancer radiotherapy, hyperbaric oxygen, haemorrhagic cystitis

## INTRODUCTION

Hyperbaric oxygen (HBO<sub>2</sub>) therapy is an effective treatment for managing haemorrhagic cystitis after radiotherapy, with reported response rates of up to 100% [1–4]. One of the most common causes of haemorrhagic cystitis is radiotherapy for prostate cancer. Despite the success rates of HBO<sub>2</sub> treatment, there are concerns about the adverse effects of this therapy. As HBO<sub>2</sub> increases tissue oxygenation and stimulates new vessel formation, a potential concern is whether these effects could translate into tumour growth or recurrence. Theoretically, with increased plasma concentrations of active oxygen and subsequent free radical formation, pro-oxidant states in HBO<sub>2</sub> may promote DNA chromosomal damage [5] and neoplastic proliferation.

Recent reviews show no cancer enhancement in a variety of animal or human studies

after HBO<sub>2</sub> treatment for various malignancies [6]. However, the effect of HBO<sub>2</sub> on prostate cancer has not been previously studied. To simulate the effects of HBO<sub>2</sub> in patients with latent prostate cancer, we assessed the actions of HBO<sub>2</sub> on residual *in vivo* prostate cancer in a murine model. Tumour reactivation, growth rate, pathological analysis and an angiogenetic assessment were compared between animals treated with HBO<sub>2</sub> and normobaric air controls.

## MATERIALS AND METHODS

Approval from institutional research advisory and animal care and use committees was obtained. Sixty 4-week-old severe combined-immunodeficient male mice (Fox Chase SCID ICR, Tac:ICR:Ha(ICR)-*prkdc*<sup>scid</sup>) were injected with  $3 \times 10^6$  cells/

100  $\mu$ L of LNCaP cells (LNCaP clone FGC, American Type Culture Collection, in 1 : 1 Matrigel: Hanks Balanced Salt Solution) subcutaneously on their right flank. After 6 weeks, 24 mice did not develop palpable tumours and these were randomized into two treatment groups; group 1 had 20 sessions of HBO<sub>2</sub> and group 2 normobaric air. All the mice were placed in specially constructed wire-mesh cages, each 28  $\times$  30  $\times$  15 cm, which ensured adequate respiratory gas-mixing, yielding standardized oxygenation and pressurization when placed in a portable animal HBO<sub>2</sub> chamber.

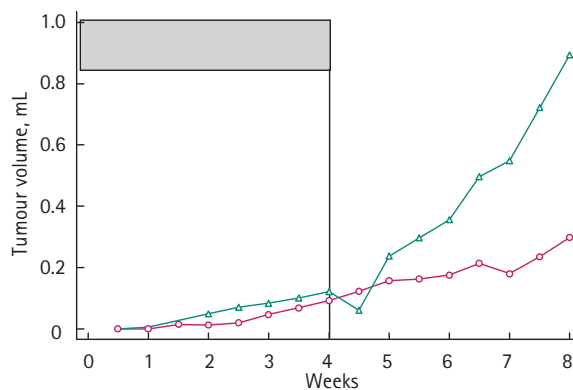
Each of the 20 treatment sessions comprised a daily 90-min session, 5 days/week for 4 weeks. HBO<sub>2</sub> sessions were designed to mirror treatments for patients in a clinical setting. Mice in group 1 were exposed to 100% oxygen at a continuous 0.236 MPa, while mice in group 2 were exposed to 21% oxygen at 0.1 MPa.

Tumour volume was measured twice a week, then all the mice were killed 4 weeks after the last therapy session. Mice were killed early if their *in vivo* prostate tumour reached 10% of their body weight, or if they remained ill despite veterinary management.

Immediately after death the mice were dissected surgically to evaluate the site of tumour injection. Dissected tumours were assessed for pathological characteristics, angiogenetic microvessel density (CD34) [7], tumour differentiation markers ( $\alpha$ -methylacyl coenzyme A racemase) [8], proliferative index (MIB-1) [9] and apoptosis-associated markers (p53, p27) [9,10]. The microvessel density was assessed in three separate tumour sites on the cut specimen section. When a large tumour was sectioned into separate mounts, the mean values of all sections were combined to give the overall mean score.

For immunohistochemistry, sections were deparaffinized in xylene, rehydrated in graded ethanol solutions, rinsed in tap water, and placed in a heated 10 mmol/L sodium citrate solution at pH 6.0 to retrieve the antigens. Immunohistochemical techniques used included sequential application of primary antibody (monoclonal mouse antibody directed against human CD34; 1 : 500 dilution; Dako Corporation, Carpinteria, CA), MIB-1 (1 : 50 dilution; Dako), p53 (1 : 300 dilution; Dako), p27 (1 : 30 dilution; Dako), and Racemase (1 : 50 dilution, Zeta, Sierra Madre, CA) at room temperature for 60 min incubation, secondary biotinylated goat antimouse antibody (1 : 300 dilution; Dako) for 30 min at room temperature, and a 30-min incubation with peroxidase-labelled streptavidin-biotin complex (1 : 500 dilution; Dako). Immunoreactivity was visualized by incubation with 3-aminoethylcarbazole in the presence of hydrogen peroxide. Sections were counterstained with light haematoxylin and mounted with a cover-slip. Positive and negative controls were run in parallel with each batch.

Data were assessed using nonparametric methods to compare the groups at each time, because of increasing variance with tumour size. A Wilcoxon nonparametric test was used for each comparison, with the exact-permutation distribution. Differences were considered statistically significant at  $P < 0.05$  (two-sided).



**FIG. 1.** Mice with no palpable tumours were randomized into 4 weeks (shaded box) of either HBO<sub>2</sub> therapy (red open circles) or normobaric controls (green open triangles). Mice treated with HBO<sub>2</sub> had no accelerated prostate LNCaP tumour growth both during and after 4 weeks of therapy.

**TABLE 1** Prostate tumours that developed in both groups were resected for histological assessment and immunohistochemistry; there were no significant differences in tumour characteristics and pathology

Immunohistochemistry	Group 1 (HBO <sub>2</sub> )	Group 2 (Air)
N	6	8
Mean (%) microvessel density	77.1	60.2
MIB-1	60	62
p27	85	77
p53	30	31
racemase intensity	2+	3+
racemase	73	69

## RESULTS

In the mice in group 1 there was a trend toward suppression of prostate tumour growth (Fig. 1) although the difference was not statistically significant ( $P = 0.261$ ). During therapy, 10 mice from group 1 remained tumour-free, compared with seven in group 2 ( $P = 0.30$ ). After completing the 4-week therapy, the mean (95% CI) tumour volumes were 0.092 (0–0.288) and 0.121 (0–0.355) mL for groups 1 and 2, respectively ( $P = 0.342$ ); after monitoring for another 4 weeks after therapy, the mean tumour volumes were 0.298 (0–0.830) and 0.894 (0–1.621), respectively ( $P = 0.261$ ). The lower limit for tumour volume was truncated at zero, as tumour volume cannot be negative. At the end of the study, six mice in group 1 and four in group 2 remained free of palpable LNCaP prostate tumours ( $P = 0.17$ ).

There were no instances of illness or tumour breakthrough bleeding. No mice were killed before the scheduled study end. Tumours excised from mice at the end of study showed that there was tumour invasion and necrosis in two and four of group 1, and five and seven in group 2. The mean values for tumour

microvessel density, proliferative index, differentiation and apoptosis markers were similar in both groups (Table 1).

## DISCUSSION

By definition, a patient treated with HBO<sub>2</sub> therapy must breathe 100% oxygen intermittently within an enclosed pressurized chamber at  $\geq 0.14$  MPa [11]. Pressurized oxygen delivery results in the hypersaturation of plasma with dissolved oxygen, which improves local and regional tissue oxygen supply in tissues with poor oxygenation resulting from previous radiation, mechanical or chemical injuries [12]. This is achieved by creating a steep oxygen gradient between the end-arterioles and capillaries, and the hypoxic tissues requiring treatment [13]. In creating this steep oxygen gradient, primary neovascularization occurs with capillary ingrowth into hypoxic tissues. Compared with normobaric air, HBO<sub>2</sub> promoted an 8–9-fold increase in vascular density in an irradiated rabbit model [14]. In a mouse model, neovascularization was apparent 5 days after initiating HBO<sub>2</sub> therapy [15]. In irradiated human oral tissues treated for mandibular

osteonecrosis, HBO<sub>2</sub> therapy resulted in a significant increase in transmucosal oxygen tension after only five HBO<sub>2</sub> treatments [16]. It is the synergistic effect of greater molecular oxygen supply and increased vascular density in the hypoxic tissue that subsequently allows adequate collagen synthesis and wound repair.

Primary neovascularization with capillary ingrowth into hypoxic tissues raises concern about reactivating latent malignancy. In an earlier study, metastatic prostate LNCaP cells were exposed to 0.6 MPa for one 90-min session; there was an increase in the fraction of the cell cycle with increased DNA synthesis, raising the possibility of increased cellular synthesis with malignant transformation [17]. However, other studies have shown no detrimental effects from increased tumour oxygenation. Indeed, prostate cancer tumour hypoxia deteriorates with increased clinical stage [18], suggesting that hyperoxia may offer beneficial effects. Laboratory research suggests that HBO<sub>2</sub> may decrease the rate of *in vitro* prostate cancer growth and increase its sensitivity to anti-neoplastic agents, especially in DU-145 prostate cells, but the effects depend on the prostate cancer cell-line [19]. In a recent review [6] most published reports showed no enhancement of cancer growth in either animals or humans after HBO<sub>2</sub> exposure. One preliminary clinical study combined synthetic oestrogen and HBO<sub>2</sub> therapy in 40 patients with advanced prostate cancer; there was a 75% reduction in bone metastasis, and 40% cancer-specific survival at 36 months [20].

In the present study we attempted to simulate the condition of patients with residual, indolent prostate cancer. Such patients may not have detectable prostate cancer recurrence after radiation therapy, but sometimes develop radiation-induced haemorrhagic cystitis as a result of their primary treatment, with subsequent HBO<sub>2</sub> therapy. The present results suggest that HBO<sub>2</sub> does not activate latent prostate cancer or cause changes in tumour immunobiology when compared with normobaric air controls.

In the present study, HBO<sub>2</sub> did not accelerate indolent prostate tumour growth during or after therapy. After HBO<sub>2</sub> treatment more mice remained free of palpable malignant disease, although the differences were not statistically significant, possibly because there were too few mice.

In conclusion, these findings suggest that HBO<sub>2</sub> may not be hazardous when managing haemorrhagic cystitis after radiation in patients with a history of pelvic radiotherapy for prostate cancer. HBO<sub>2</sub> does not seem to increase the risk of reactivation of any residual prostate cancer that is undetected by biochemical or clinical methods.

#### ACKNOWLEDGEMENTS

The authors thank Richard Dunford and Rodney Wescom from the Center for Hyperbaric Medicine at Virginia Mason Medical Center, William W. Kwok, PhD from Benaroya Research Institute at Virginia Mason, Christina Isacson, MD from Department of Pathology at Virginia Mason Medical Center, Junqi Qian, MD from Bostwick Laboratories, Janna Quinn from Department of Urology at University of Washington and statistician William Barlow, PhD for their knowledgeable expertise and excellent support to make this study possible.

This study was supported by the Edward H. Morgan Chair in Pulmonary and Critical Care Medicine of Virginia Mason Medical Center.

#### CONFLICT OF INTEREST

D.G. Bostwick is the owner of Bostwick Laboratories where pathological specimens were sent.

#### REFERENCES

- 1 Crew JP, Jephcott CR, Reynard JM. Radiation-induced haemorrhagic cystitis. *Eur Urol* 2001; **40**: 111–23
- 2 Corman JM, McClure D, Pritchett R, Kozlowski P, Hampson NB. Treatment of radiation induced hemorrhagic cystitis with hyperbaric oxygen. *J Urol* 2003; **169**: 2200–2
- 3 Bevers RF, Bakker DJ, Kurth KH. Hyperbaric oxygen treatment for hemorrhagic radiation cystitis. *Lancet* 1995; **346**: 803–5
- 4 Mayer R, Klemen H, Quehenberger F *et al*. Hyperbaric oxygen – an effective tool to treat radiation morbidity in prostate cancer. *Radiother Oncol* 2001; **61**: 151–6
- 5 Cerutti PA. Pro-oxidant states and tumor promotion. *Science* 1985; **227**: 375–81
- 6 Feldmeier J, Carl U, Hartmann K, Sminia P. Hyperbaric oxygen. Does it promote growth or recurrence of malignancy? *Undersea Hyperb Med* 2003; **30**: 1–18
- 7 Offersen BV, Borre M, Sorensen FB, Overgaard J. Comparison of methods of microvascular staining and quantification in prostate carcinoma: relevance to prognosis. *APMIS* 2002; **110**: 177–85
- 8 Rubin MA, Zhou M, Dhanasekaran SM *et al*.  $\alpha$ -Methylacyl coenzyme A racemase as a tissue biomarker for prostate cancer. *JAMA* 2002; **287**: 1662–70
- 9 Claudio PP, Zamparelli A, Garcia FU *et al*. Expression of cell-cycle-regulated proteins pRb2/p130, 107, 27 (kip1), 53, mdm–2, and Ki–67 (MIB–1) in prostate gland adenocarcinoma. *Clin Cancer Res* 2002; **8**: 1808–15
- 10 Yang RM, Naitoh J, Murphy M *et al*. Low p27 expression predicts poor disease-free survival in patients with prostate cancer. *J Urol* 1998; **159**: 941–5
- 11 Feldmeier JJ. Hyperbaric oxygen 2003. Indications and Results. The Hyperbaric Oxygen Therapy Committee report. Undersea and Hyperbaric Medical Society: Kensington, Maryland, 2003: 1–4
- 12 Robertson PW, Hart BB. Assessment of tissue oxygenation. *Resp Care Clin N Am* 1999; **5**: 221–63
- 13 O'Reilly KJ, Hampson NB, Corman JM. Hyperbaric oxygen in urology. *AUA Update Series* 2002; Vol. XXI: Lesson 4
- 14 Marx RE, Ehler WJ, Tayapongsak P, Pierce LW. Relationship of oxygen dose to angiogenesis induction in irradiated tissue. *Am J Surg* 1990; **160**: 519–24
- 15 Shoshani O, Shupak A, Ullmann Y *et al*. The effect of hyperbaric oxygenation on the viability of human fat injected into nude mice. *Plas Reconstr Surg* 2000; **106**: 1390–6
- 16 Thorn JJ, Kallehave F, Westergaard P, Hansen EH, Gottrup F. The effect of hyperbaric oxygen on irradiated oral tissues: transmucosal oxygen tension measurements. *J Oral Maxillofac Surg* 1997; **55**: 1103–7
- 17 Kalns JE, Piepmeier EH. Exposure to hyperbaric oxygen induces cell cycle perturbation in prostate cancer cells. *In Vitro Cell Dev Biol Anim* 1999; **35**: 98–101
- 18 Movsas B, Chapman JD, Greenberg RE *et al*. Increasing levels of hypoxia in prostate carcinoma correlate significantly with increasing clinical stage and patient

- age-an Eppendorf pO<sub>2</sub> study. *Cancer* 2000; **89**: 2018–24
- 19 **Kalns J, Krock L, Piepmeier E Jr.** The effect of hyperbaric oxygen on growth and chemosensitivity of metastatic prostate cancer. *Anticancer Res* 1998; **18**: 363–7
- 20 **Osorio-Acosta V, Gomez-Sampera A, Castellanos-Gutierrez R et al.** Estrogenos y oxigenacion hiperbarica en el tratamiento del cancer de prostata en etapas avanzadas. Informe preliminary. *Gaceta Med* 1990; **1**: 88–92

**Correspondence:** John M. Corman, Section of Urology and Renal Transplantation, Virginia Mason Medical Center, C7-URO, 1100 Ninth Avenue, PO Box 900, Seattle, WA 98111, USA. e-mail: urojmc@vmmc.org

**Abbreviations:** HBO<sub>2</sub>, hyperbaric oxygen.