

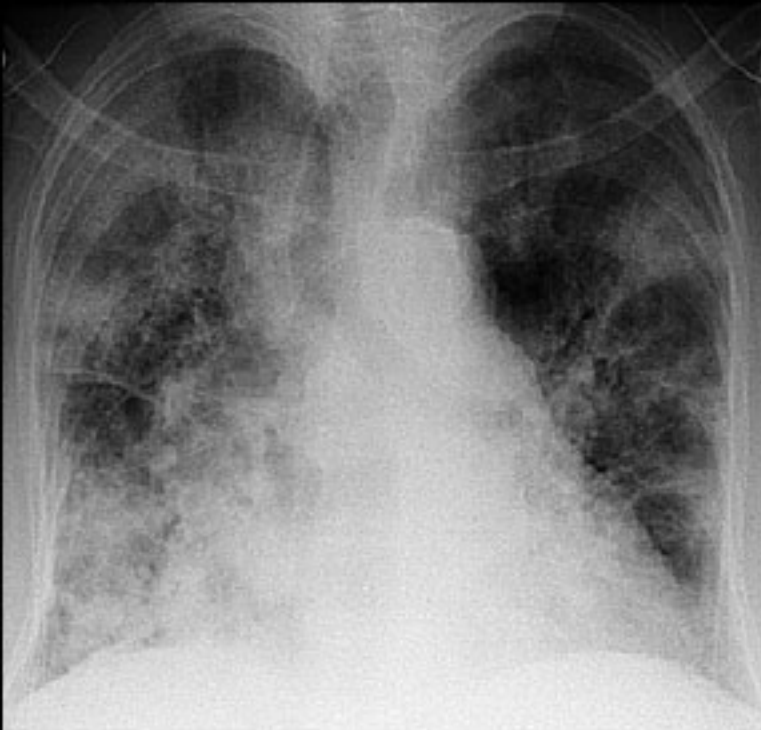Figure 1—The admission chest radiograph is showing extensive bilateral alveolar and interstitial infiltrates.

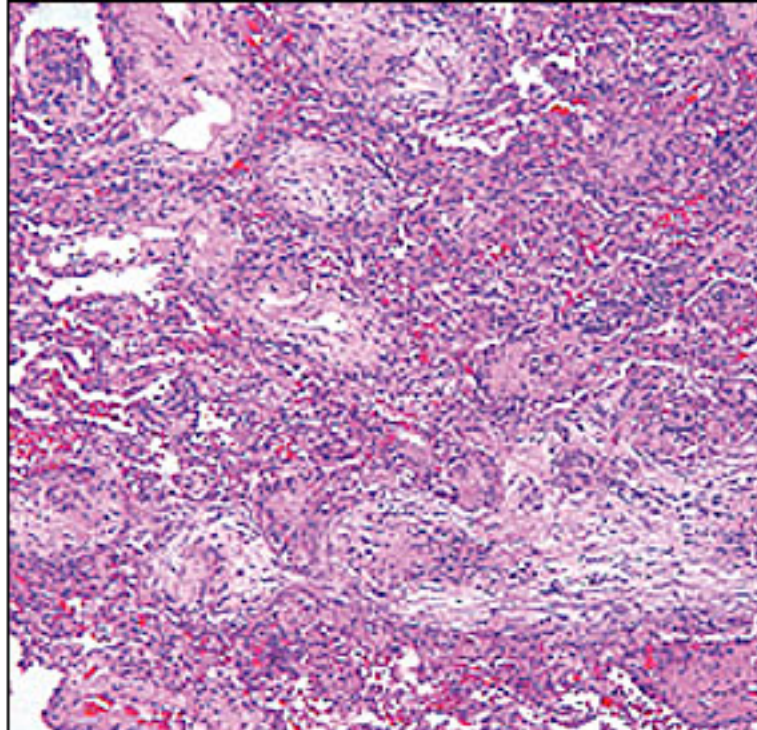


Figure 3—Polypoid proliferations of edematous stroma, with mixed inflammation branching in the airways and filling the surrounding airspaces (hematoxylin and eosin staining; magnification, 1002).

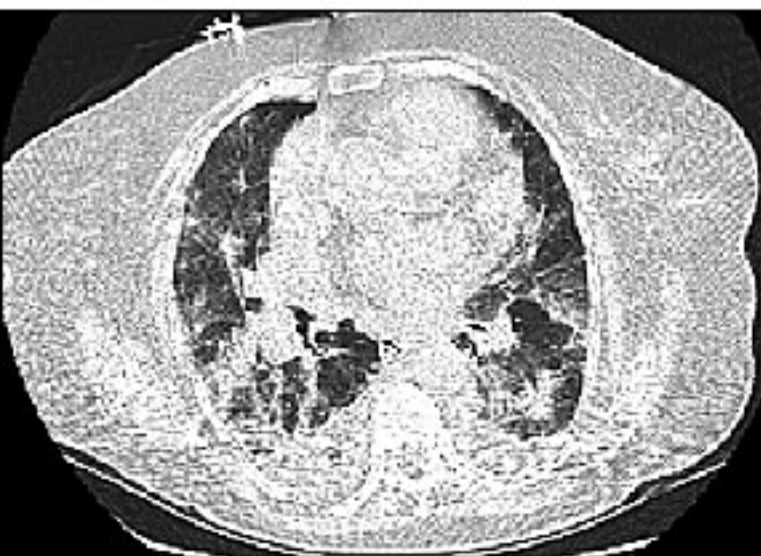

Figure 2—Chest CT scan demonstrates extensive ground-glass opacities and airspace consolidation of both lungs.

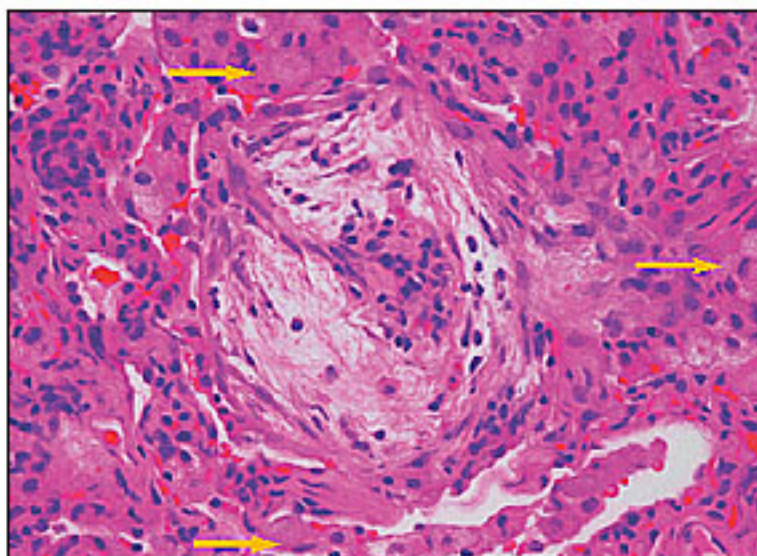


Figure 4—Edematous granulation tissue fills the airspace seen in the center. Foamy intraalveolar macrophages (arrows) can also be seen in numerous surrounding airspaces (hematoxylin and eosin staining; magnification, 4002).